

# *Diagnosis and Management of Diabetic Foot Infections*

**2020**

## **CONTRIBUTING AUTHORS**

**ANDREW J.M. BOULTON, MD, DSC (HON),  
FACP, FRCP**

Professor of Medicine, University of Manchester,  
Manchester, UK, and Visiting Professor of Medicine,  
University of Miami Miller School of Medicine,  
Miami, FL

**DAVID G. ARMSTRONG, DPM, MD, PHD**  
Professor of Surgery, Keck School of Medicine of  
the University of Southern California and Director,  
Southwestern Academic Limb Salvage Alliance  
(SALSA), Los Angeles, CA

**MATTHEW J. HARDMAN, PHD**  
Professor of Wound Healing and Director of  
Research, Hull York Medical School, Hull, UK

**MATTHEW MALONE, PHD, FFPM RCPS (GLASG)**  
Director of Research, South Western Sydney Local  
Health District, Limb Preservation and Wound  
Research Academic Unit, Ingham Institute of  
Applied Medical Research, Liverpool, Sydney, NSW,  
Australia, and Conjoint Senior Lecturer, Western  
Sydney University, School of Medicine, Infectious  
Diseases and Microbiology, Campbelltown  
Campus, Sydney, Australia

**JOHN M. EMBIL, MD, FACP, FRCPC**  
Professor, Departments of Medicine (Section of  
Infectious Diseases) and Medical Microbiology, Max  
Rady College of Medicine, University of Manitoba,  
Winnipeg, Manitoba, Canada

**CHRISTOPHER E. ATTINGER, MD**  
Chief, Division of Wound Healing, MedStar  
Georgetown University Hospital, Washington, DC

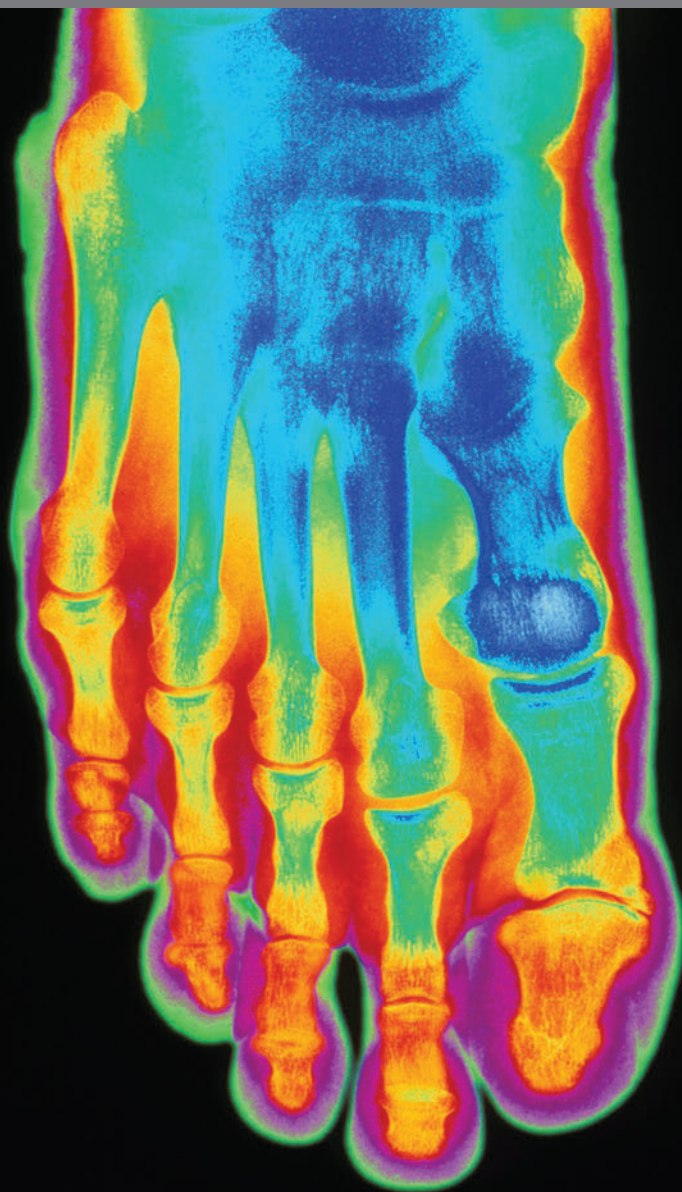
**BENJAMIN A. LIPSKY, MD, FACP, FIDSA, FRCP  
(LONDON), FFPM RCPS (GLASG)**  
Emeritus Professor of Medicine, University of  
Washington School of Medicine, Seattle, WA, and  
Green Templeton College, University of Oxford, UK

**JAVIER ARAGÓN-SÁNCHEZ, MD PHD**  
Chief, Department of Surgery and Diabetic Foot Unit,  
La Paloma Hospital, Las Palmas de Gran Canaria,  
Spain

**HO KWONG LI, MBBS, MRCP (UK), DTM&H**  
Clinical Research Training Fellow, Medical Research  
Council—Centre for Molecular Bacteriology &  
Infection and Department of Infectious Disease,  
Imperial College London, London, UK

**GREGORY SCHULTZ, PHD**  
Professor of Obstetrics and Gynaecology and  
Director of the Institute for Wound Research,  
University of Florida, Gainesville, FL

**ROBERT S. KIRSNER, MD, PHD**  
Chairman and Harvey Blank Professor, Dr. Phillip  
Frost Department of Dermatology and Cutaneous  
Surgery, University of Miami Miller School of  
Medicine, Miami, FL



This publication has been supported by unrestricted educational grants to the American Diabetes Association from Healogics, Inc., and Organogenesis, Inc.

Diagnosis and Management of Diabetic Foot Infections is published by the American Diabetes Association, 2451 Crystal Drive, Arlington, VA 22202. Contact: 1-800-DIABETES, [professional.diabetes.org](http://professional.diabetes.org).

*The opinions expressed are those of the authors and do not necessarily reflect those of Healogics, Inc., Organogenesis, Inc., or the American Diabetes Association. The content was developed by the authors and does not represent the policy or position of the American Diabetes Association, any of its boards or committees, or any of its journals or their editors or editorial boards.*

©2020 by American Diabetes Association. All rights reserved. None of the contents may be reproduced without the written permission of the American Diabetes Association.

*To request permission to reuse or reproduce any portion of this publication, please contact [permissions@diabetes.org](mailto:permissions@diabetes.org).*

*Front cover image*

*Credit: Mehau Kulyk/Science Source; Description: Foot bones. Colored X-ray of the bones in a healthy human foot, seen in top view.*

*Back cover image*

*Credit: Du Cane Medical Imaging Ltd/Science Source; Description: Normal foot. Colored X-ray of a healthy human foot seen from the side (lateral projection).*

# Diagnosis and Management of Diabetic Foot Infections

**ABSTRACT** | This compendium is a follow-up to the 2018 American Diabetes Association compendium *Diagnosis and Management of Diabetic Foot Complications*. Whereas the first compendium offered a broad general overview of diabetic foot conditions, this second volume presents a detailed discussion of the prevention and treatment of diabetic foot infections (DFIs), a major contributor to high amputation rates among people with diabetes. The treatise begins from the viewpoint of basic science, describing the impact of infection on the healing process of experimental wounds. There follow overviews of biofilm development in chronic diabetic foot ulcers (DFUs), the microbiology of DFIs, and the crucial role of debridement in ensuring positive outcomes of DFI treatment. Next, the authors provide a practical guide to the diagnosis and clinical management of DFIs. Current controversies regarding the treatment of osteomyelitis are addressed, including the relative value of antibiotics versus surgery and the use of intravenous versus oral antibiotics. The compendium closes with a look at new topical treatments and the role of emerging technologies in infection control.

After the success and positive reception of the American Diabetes Association's 2018 compendium *Diagnosis and Management of Diabetic Foot Complications* (1) the association asked us to proceed with a second volume. The first publication offered a broad general overview of diabetic foot issues, encompassing the etiopathogenesis of complications, screening, and wound classification; management of diabetic foot ulcers (DFUs) and diabetic foot infections (DFIs); recognition and treatment of peripheral artery disease (PAD) and Charcot neuroarthropathy; off-loading, wound management, and adjunctive therapies; and maintenance of the foot in remission.

In the past few years, there has been a renaissance in diabetic foot care with respect to evidence-based treatments (2). Examples include the LeucoPatch system (3), topical oxygen delivery (4,5), and, for neuroischemic ulcers, sodium octasulfate dressings (6). There has also been progress in the management of DFUs with infection. For example, a randomized controlled trial (RCT) confirmed that treatment with antibiotics is noninferior to local surgery for localized diabetic foot osteomyelitis (DFO) (7). (See related discussion on p. 12.) Most recently, the OVIVA (Oral Versus Intravenous Antibiotics) trial confirmed that, for complex bone and joint infections, oral antibiotic therapy had sim-

Andrew J.M. Boulton, MD, DSc (Hon), FACP, FRCP<sup>1,2</sup>

David G. Armstrong, DPM, MD, PhD<sup>3,4</sup>

Matthew J. Hardman, PhD<sup>5</sup>

Matthew Malone, PhD, FFPM RCPS (Glasg)<sup>6,7</sup>

John M. Embil, MD, FACP, FRCPC<sup>8</sup>

Christopher E. Attinger, MD<sup>9</sup>

Benjamin A. Lipsky, MD, FACP, FIDSA, FRCP (London), FFPM RCPS (Glasg)<sup>10,11</sup>

Javier Aragón-Sánchez, MD, PhD<sup>12</sup>

Ho Kwong Li, MBBS, MRCP (UK), DTM&H<sup>13,14</sup>

Gregory Schultz, PhD<sup>15</sup>

Robert S. Kirsner, MD, PhD<sup>2</sup>

---

<sup>1</sup>University of Manchester, Manchester, UK

<sup>2</sup>University of Miami Miller School of Medicine, Miami, FL

<sup>3</sup>Keck School of Medicine of the University of Southern California, Los Angeles, CA

<sup>4</sup>Southwestern Academic Limb Salvage Alliance (SALSA), Los Angeles, CA

<sup>5</sup>Hull York Medical School, Hull, UK

<sup>6</sup>South Western Sydney Local Health District, Limb Preservation and Wound Research Academic Unit, Ingham Institute of Applied Medical Research, Liverpool, Sydney, NSW, Australia

<sup>7</sup>Western Sydney University, School of Medicine, Infectious Diseases and Microbiology, Campbelltown Campus, Sydney, Australia

<sup>8</sup>Max Rady College of Medicine, University of Manitoba, Winnipeg, Manitoba, Canada

<sup>9</sup>MedStar Georgetown University Hospital, Washington, DC

<sup>10</sup>University of Washington School of Medicine, Seattle, WA

<sup>11</sup>Green Templeton College, University of Oxford, UK

<sup>12</sup>Department of Surgery and Diabetic Foot Unit, La Paloma Hospital, Las Palmas de Gran Canaria, Spain

<sup>13</sup>Medical Research Council—Centre for Molecular Bacteriology & Infection, London, UK

<sup>14</sup>Department of Infectious Disease, Imperial College London, London, UK

<sup>15</sup>University of Florida, Gainesville, FL

**Address correspondence to Andrew J.M. Boulton, ABoulton@med.miami.edu, and David G. Armstrong, armstrong@usa.net.**

ilar outcomes to intravenous (IV) therapy (8). (See related discussion on p. 13.) Because foot infections are a major contributor to amputation, we decided to make infected DFUs the focus of this second foot care compendium.

The first sections herein cover the impact of infection on healing of experimental wounds (p. 2), the importance of biofilms (p. 4), and a general overview of the microbiology of DFIs (p. 6). Although debridement of DFUs was covered in the first compendium, we deemed it important enough to include here as well, given its pivotal role in the management of DFIs. Whereas molecular markers might inform the extent of wound debridement in the future (9), at present, clinical assessment is used to ensure that adequate debridement is achieved, as reviewed starting on p. 7. Subsequent sections cover the management of infected DFUs (p. 9) and discussions of antibiotics versus surgery for osteomyelitis (p. 12) and the OVIVA trial (p. 13). There is little doubt that the OVIVA trial will challenge the current management of osteomyelitis, in which IV antibiotics are still commonly used. The remaining sections cover potential topical treatments for DFIs (p. 15) and the role of modern technology in infection control (p. 17).

In addition to this compendium and the previous one (1), we want to direct readers' attention to two forthcoming publications that will surely be of interest. First, in the wake of the 8th International Symposium on the Diabetic Foot held in May 2019 in The Netherlands, the International Working Group on the Diabetic Foot (IWGDF) has recently published its revised and updated guidelines on the management of DFIs (10). In addition,

the Infectious Disease Society of America will soon be updating its 2012 guidelines (11) on the treatment of infected DFUs.

---

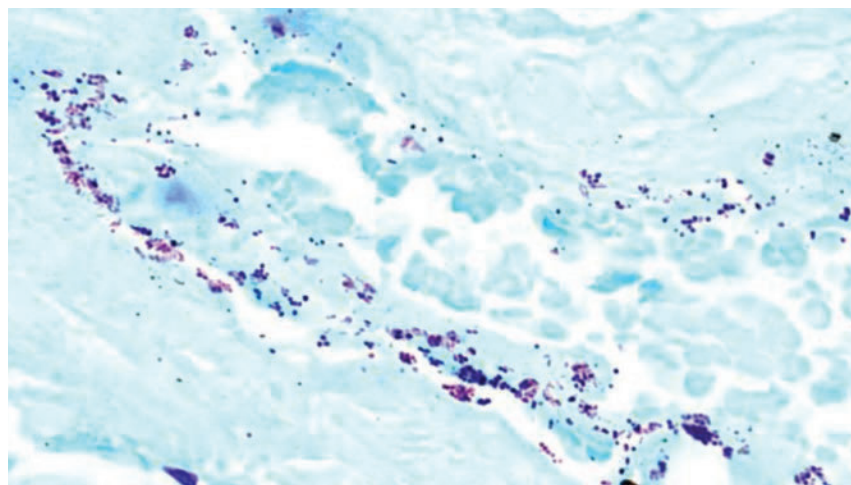
## How Infection Impairs Wound Healing

DFUs are a complex, multifactorial clinical problem that, despite decades of research, remain poorly understood at the basic science level. Over millennia, our bodies have evolved a highly orchestrated healing response to skin wounds through which inflammation, cell proliferation, migration, angiogenesis, matrix deposition, and remodeling are sequentially activated to repair injured tissue. We know that, in DFUs, repair becomes dysregulated with widespread tissue necrosis, hyperproliferative wound callus, and excessive inflammation. This drives a matrix metalloproteinase (MMP)-rich proteolytic wound bed, which impedes granulation, delays vascularization, and results in a hypoxic local environment. At the cellular level,

DFUs are characterized by accumulation of senescent cells and lack responsiveness to the normal cues that drive timely repair. At the molecular level, there are still major gaps in our knowledge of DFU ontogenesis, underscored by a distinct lack of biological therapies for wound care.

How does this profound state of dysregulation occur, and perhaps more importantly, why do some DFUs resolve quickly, whereas others persist for months or even years? It seems increasingly likely that the answer lies in the concept of wound infection, or more specifically, in every wound's unique bacterial signature, or microbiome.

Infection is defined clinically by the cardinal signs and symptoms of redness, heat, swelling, and pain, with nearly half of all DFUs classified as infected (12). Diagnosis of DFU infection strongly correlates with subsequent amputation and increased mortality. The current dogma is that open wounds become contaminated with pathogenic microorganisms, which then colonize the tissue (Figure 1). This transition from contamination



**FIGURE 1** Gram stain allows visualization of bacteria within a DFU tissue sample. Gram-positive bacteria stain dark blue, gram-negative bacteria stain pink, and DFU tissue stains light blue.

to colonization is aided by the unique DFU microenvironment: hyperglycemic, ischemic tissue with dry, cracked neuropathic epidermis. The transition to wound infection is further supported by functional deficiencies in diabetic immune cells, which at this early stage of infection are unable to efficiently phagocytose bacteria or release antimicrobial factors to manage the invading pathogens. There is good evidence that the tipping point to local infection is marked by a shift in wound bacterial composition, specifically toward increased local anaerobic bacteria (13). Interestingly, wound debridement has been shown to be particularly effective at removing these unwanted anaerobes. If left untreated, local infection can quickly transit to widespread overt infection with involvement of other tissues such as bone.

The concept that wound bacteria influence healing (both positively and negatively) in the absence of infection may seem counterintuitive. Yet, recent culture-independent studies have revealed that DFU microbiomes in the absence of infection are dynamic, heterogeneous, and incredibly complex. Wound bacterial signatures strongly link to healing outcome in noninfected DFUs (14), suggesting a host-microbe relationship that is more subtle than previously thought. Indeed, it is likely that DFU bacteria directly modify the wound milieu, altering the local microclimate (e.g., pH) and producing metabolites that directly affect cellular healing.

So, why do some wounds present with high bioburden but no signs of infection and vice versa? The answer appears to lie in the

complexity and diversity of the chronic wound microbial ecosystem. Bacteria, fungi, and other microorganisms do not exist in isolation; they use an array of signaling molecules to interact with each other and with host tissue. Established microbial communities exist as structurally complex biofilms, altering their metabolic state, gene expression, and environment (15). Biofilm bacteria are surrounded by a protective matrix that confers both protection from the host immune system and recalcitrance to exogenous antimicrobials. In many ways, the number of microorganisms present is irrelevant; it is the environment in which those organisms exist that directs phenotype and virulence, and these factors ultimately trigger the host response that manifests as clinical signs of infection.

Wound microorganisms directly modulate wound cell behavior and modify healing capacity. Compared to the relatively new area of DFU microbial composition profiling, far more is known about how bacteria interact with human skin cells and tissues, an area for which the relevant laboratory techniques have been readily available for years. Wound cells sense the bacterial composition of a wound via an array of pattern recognition receptors (PRRs). These PRRs recognize specific bacterial components known as pathogen-associated molecular pattern molecules, which in turn upregulate host antimicrobial peptides to actively modulate the skin/wound microbial composition.

Defects in a number of PRRs have been linked to diabetes, offering a mechanism for the observed bacterial dysbiosis. Specific bac-

terial virulence mechanisms have been studied in detail. For example, *Pseudomonas aeruginosa* is optimized for adherence to the surface of the skin epithelium but is also able to invade into the deeper wound bed tissue (16). *Pseudomonas* can even exist inside host cells (keratinocytes), where it effectively evades the immune system. Cells exposed to live *P. aeruginosa* or *Pseudomonas*-derived lipopolysaccharide in vitro demonstrate impaired migration, increased proliferation, and increased cell death. These findings are supported by in vivo models demonstrating impaired wound healing after the administration of live bacteria or bacterial components directly on experimental wounds.

Current research, underpinned by the powerful new technologies of shotgun metagenomics and long-read sequencing, is opening our eyes to the bewildering complexity of the skin and wound microbiota. Historically, we have relied on culture-based methods to identify wound bacteria. Indeed, bacterial culture remains the front-line diagnostic technique for wound infection. The problem with these culture-based methods is that they identify only a small fraction of constituent microbes. Bacterial culture has promoted the idea that *Staphylococcus aureus*, *Streptococcus*, and *P. aeruginosa* are the main organisms in DFUs. However, in a game-changing shotgun sequencing study of 100 DFUs, Kalan et al. (17) reported detailed genus-, species-, and even strain-level characterization of the DFU microbiome. Intriguingly, these authors showed that a strain of *S. aureus* (SA10757) linked by metagenomics to clinical healing

outcome also directly delayed healing in a mouse model. A key theme in emerging microbiome studies is the strong links among reduced diversity, increased temporal stability, and poor healing.

The individual nature of the microbiome poses an ongoing challenge. When the microbiome signature differs substantially among individuals, how does one look for common “healing” or “nonhealing” signatures? The answer is to employ carefully designed (but expensive and time consuming) longitudinal profiling studies looking for common changes in composition or diversity.

So, what does the future hold for the treatment of infected DFUs? It is widely accepted that the number of infected DFUs requiring treatment will continue to increase, driven by the expanding number of diabetic and elderly patients. In the short term, emerging technologies to detect bacteria (e.g., MolecuLight *i:X*; Smith & Nephew, Hertfordshire, UK) will be essential to guide treatment. In the next 10 years or so, there will likely be widespread implementation of point-of-care microbiota profiling methodologies in clinics. With these methods, bacterial community-level genetic resistance profiling will revolutionize the ways in which we diagnose, manage, and treat infection. Ultimately, we will reach a level of understanding of the host-microbe continuum that permits a personalized treatment approach, augmenting the endogenous host defense while supporting skin commensals.

---

## Biofilms in the Context of DFUs

### WHAT ARE BIOFILMS?

There is no current consensus among researchers regarding the definition of biofilm, but collectively from within the literature, definitions often describe medically related biofilms as “aggregates of microorganisms embedded in a matrix of extracellular polymeric substances.” Biofilms can attach to host tissue or in-dwelling medical devices or exist in fluids adjacent to those surfaces. In contrast to planktonic microorganisms, biofilms demonstrate reduced growth rates and altered gene expression. These changes may help to explain why biofilms show an enhanced tolerance to antimicrobials and the host immune response.

### BIOFILMS IN HUMAN HEALTH AND DISEASE

Biofilms can be found in medical, industrial, and natural environments and may affect human health both positively and negatively. When biofilms are implicated in human disease, they are widely acknowledged as a cause of chronic and persistent infections (18). It is generally believed that biofilms are not the cause of acute infections; these are caused by planktonic microorganisms.

When breaches in the skin envelope occur in the feet of people with diabetes, most open wounds are colonized by microorganisms; however, this does not mean the microorganisms will act pathogenically and incite a host response (i.e., clinical signs of infection). Likewise, not all wounds will form biofilms. Evidence has

demonstrated that most acute wounds are not complicated by biofilms. It is also pertinent to note that, whereas biofilms may form in wounds such as DFUs, not all biofilms may act pathogenically or be detrimental to wound healing.

### BIOFILMS AND THEIR OCCURRENCE IN DIABETIC FOOT WOUNDS

Biofilms are not the primary mechanism behind the development of foot ulceration; rather, ulceration occurs as a result of precipitating factors that include peripheral neuropathy (loss of protective sensation), altered foot architecture, trauma, and PAD. These factors contribute to breaks in the protective barrier of the skin. However, once pathogenic biofilms become established in DFUs, they may contribute as a cause of chronic and persistent infections, which may delay ulcer healing. In vitro and animal model research has demonstrated that biofilms can delay wound healing. However, the translational evidence from human clinical studies demonstrating biofilms as causal mechanisms for delayed ulcer healing or as drivers of chronic infections in the feet of people with diabetes is scant and requires further exploration (17,19,20).

### DIAGNOSIS OF BIOFILMS

Contrary to general belief, biofilms are not visible to naked-eye observation. Wound bed material, such as slough or fibrin, or observations of a shiny translucent layer may be mistaken for biofilms. There is no scientific validation to suggest that these clinical fea-

tures are biofilms or proponents of biofilm. Additionally, biofilms do not form homogeneously on the surface of wounds. They are heterogeneously distributed in aggregates and may form on both the wound surface and deeper structures, making diagnosis and treatment more difficult.

In keeping with current expert guidelines (10), the optimal sampling technique for determining pathogens from infected DFUs is to obtain an appropriate tissue specimen. Obtaining tissue specimens is also the only direct way to visualize the presence of biofilms using microscopy (18). Biofilm visualization is best performed using microscopy approaches such as scanning electron, confocal, transmission, or light microscopy. The major limitation is that these techniques are typically confined to bench research and are not clinically practical.

Adding to the complexity of diagnosing biofilm infections, there are currently no routine diagnostic tests or biomarkers to

confirm their presence. Furthermore, microbiological specimens sent for conventional culture do not necessarily identify microorganisms in biofilms (because of their reduced growth), and most clinical microbiology laboratories will not have the capability to perform biofilm-specific culture approaches.

To circumvent the lack of diagnostics, the clinical characteristics that best define a chronic infection may aid clinicians in identifying potential biofilm infections in DFUs (Figure 2).

### MICROBIOLOGY OF BIOFILMS IN DFUS

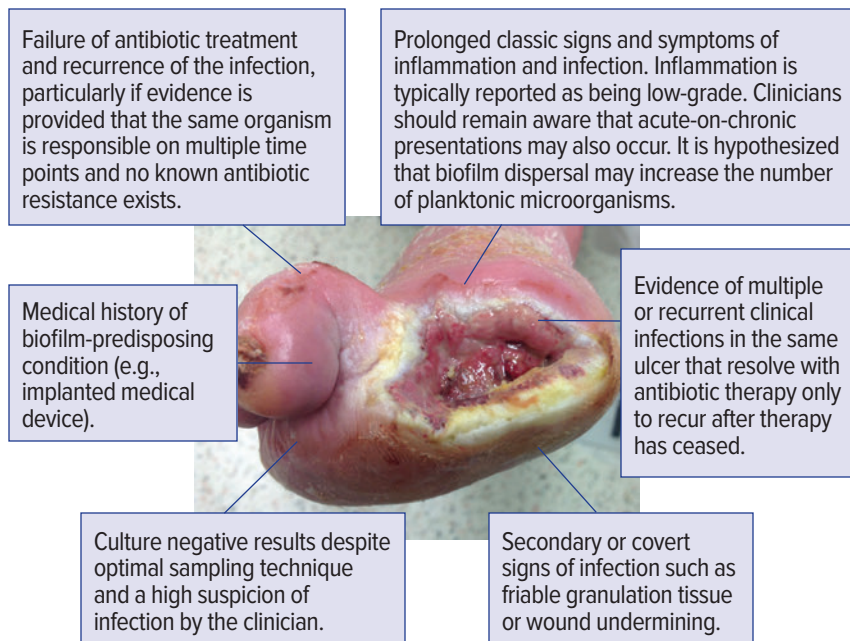
Most studies exploring the presence of biofilms in DFUs have employed molecular (DNA) sequencing technologies and thus report an extended view of the diabetic foot microbiome. Nonetheless, the predominant microorganisms identified from DFUs with biofilm formations are those commonly reported

within the preexisting diabetic foot literature. Most DFUs contain polymicrobial biofilms. Aerobic gram-positive cocci (staphylococci and streptococci) are predominant. In addition to aerobic species, other bacteria commonly identified in the same foot ulcers include fastidious anaerobes (namely, those belonging to *Clostridiales* Family XI), *Corynebacterium* sp., and gram-negative rods (namely, *Klebsiella* spp., *Acinetobacter* spp., *Enterobacter* spp., *P. aeruginosa*, and *Escherichia coli*).

### MANAGEMENT OF BIOFILMS

Across the spectrum of human diseases caused by biofilms (i.e., periodontal, in-dwelling medical device, and human tissue or bone infections), the standard treatment approach is to physically remove the biofilms. Removing biofilms from infected tissue or bone via debridement is one of the most important treatment strategies (15). However, it may not be possible to completely eradicate biofilms from tissue or bone because treating clinicians are unable to see biofilms and therefore may not debride all infected tissue and because biofilms are tolerant to antimicrobials and the host immune response. Systemic antibiotics may have little effect against chronic biofilm infections in DFUs; therefore, antimicrobial stewardship must be considered with controlled use to help manage planktonic bacteria (acute infection) and to prevent associated systemic infections.

In the context of local wound care for DFUs, there is also a lack of high-quality evidence from human in vivo clinical trials pertaining to the effectiveness of topical antimicrobial agents against



**FIGURE 2** Clinical signs and symptoms that may indicate chronic biofilm infection of a DFU.

biofilms. There are currently no agents with Level 1 evidence (i.e., based on RCTs, systematic reviews, or meta-analyses). In the absence of RCTs or case-control studies, clinicians should consider the cost burden of using topical agents for which there are limited data.

## Evolving Microbiology of DFIs

In evaluating and treating DFUs, it is important to distinguish between microbial colonization and infection. Although ulcers may be colonized with microorganisms,

infections that require treatment are characterized by bacterial invasion of skin, other soft tissues, or bone. The clinical manifestations of DFIs include local warmth, erythema, induration, pain or tenderness, and purulence. The presence of these clinical signs and symptoms should alert clinicians to consider proceeding with further evaluation and treatment (11,21).

There are several classification systems to define the presence and severity of infection in the feet of people with diabetes. The IWGDF categorizes feet as uninfected if there are no local or systemic manifestations of infection and as infected when there

are two or more clinical findings of infection (Table 1) (10).

Antimicrobial therapy is required for the treatment of DFIs (11,21) but is not required for uninfected wounds (10,11,21). Initial treatment of DFIs typically includes empiric antibiotic therapy, because specimen culture results usually are not yet available. For infected wounds, specimen culture results help to identify the causative pathogens, allowing for any necessary modification to optimize antimicrobial therapy. Specimen culture results for clinically uninfected DFUs do not meaningfully benefit decisions on therapy (10,11,21).

DFUs typically are colonized

**TABLE 1** IWGDF Classification for Defining the Presence and Severity of DFIs

| IWGDF CLASSIFICATION   | DEFINITION  |
|--|---|
| UNINFECTED   |   |
| 1 – Uninfected   | No local or systemic symptoms or signs of infection   |
| INFECTED*  |   |
| <ul style="list-style-type: none"> <li>▶ At least two of these features are present:               <ul style="list-style-type: none"> <li>• Local swelling or induration</li> <li>• Erythema &gt;0.5 cm around the wound</li> <li>• Local tenderness or pain</li> <li>• Local increased warmth</li> <li>• Purulent discharge</li> </ul> </li> <li>▶ No other cause of skin inflammation (e.g., trauma, gout, Charcot arthropathy, fracture, thrombosis, or venous stasis disease)</li> </ul> |   |
| 2 – Mild infection   | <ul style="list-style-type: none"> <li>▶ Infection with no systemic manifestations (see below) involving:               <ul style="list-style-type: none"> <li>• Only skin or subcutaneous tissue (not any deeper tissues), and</li> <li>• Any erythema present does not extend &gt;2 cm<sup>3</sup> around the wound<sup>†</sup></li> </ul> </li> </ul>  |
| 3 – Moderate infection   | <ul style="list-style-type: none"> <li>▶ Infection with no systemic manifestations, and involving:               <ul style="list-style-type: none"> <li>• Erythema extending ≥2 cm from the wound margin, and/or</li> <li>• Tissue deeper than skin and subcutaneous tissues (e.g., tendon, muscle, joint, bone; see below)</li> </ul> </li> </ul>  |
| 4 – Severe infection   | <ul style="list-style-type: none"> <li>▶ Any foot infection with two or more associated systemic manifestations (per systemic inflammatory response syndrome [SIRS] criteria):               <ul style="list-style-type: none"> <li>• Temperature &gt;38° C or &lt;36° C</li> <li>• Heart rate &gt;90 bpm</li> <li>• Respiratory rate &gt;20 breaths/min or partial pressure of carbon dioxide &lt;4.3 kPa (32 mmHg)</li> <li>• White blood cell count &gt;12,000/mm<sup>3</sup>, &lt;4,000/mm<sup>3</sup>, or &gt;10% immature (band) forms</li> </ul> </li> </ul> |
| 3(O) or 4(O) – Moderate or severe infection with associated osteomyelitis  | <ul style="list-style-type: none"> <li>▶ Moderate or severe infection that also involves bone (osteomyelitis)<sup>‡</sup></li> </ul>  |

Adapted from ref. 10. \*Infection refers to involvement of any part of the foot, not just a wound or an ulcer. <sup>†</sup>In any direction from the rim of the wound. The presence of major foot ischemia makes diagnosis and treatment of infection more difficult. <sup>‡</sup>If osteomyelitis is present in the absence of two or more signs or symptoms of local or systemic inflammation, the foot is classified as having grade 3(O) (if <2 SIRS criteria) or grade 4(O) (if ≥2 SIRS criteria).



initially by gram-positive bacteria such as *S. aureus* (methicillin-susceptible *S. aureus* or methicillin-resistant *S. aureus* [MRSA]) and the  $\beta$ -hemolytic streptococci such as group A *Streptococcus* (*Streptococcus pyogenes*), group B *Streptococcus* (*Streptococcus agalactiae*), or group C or G *Streptococcus*. As an ulcer becomes chronic, it may contain devitalized, necrotic tissue and become colonized with gram-negative bacteria such as *P. aeruginosa*; the *Enterobacteriaceae*, including *E. coli*, *Proteus* spp., and *Klebsiella* spp.; and anaerobic bacteria such as *Bacteroides* spp. and *Clostridium* spp. (11,21). With hospitalization and treatment with broad-spectrum antibiotics, ulcer flora may change to include antimicrobial-resistant pathogens such as MRSA, vancomycin-resistant *Enterococcus*, and gram-negative bacteria that produce extended spectrum  $\beta$ -lactamase or carbapenemase enzymes (22–24).

Most current knowledge about the microbiology of DFIs has been derived from studies conducted in North America and Europe, where the most prevalent pathogens are gram-positive bacteria such as *S. aureus* (10,11,21). In these Western countries, MRSA has become a frequently occurring DFI pathogen (25,26). Infection with MRSA also may occur in patients who do not have any typical risk factors for acquisition of MRSA (e.g., hospitalization or previous antibiotic therapy) because of increased prevalence of MRSA in the community (27). MRSA infections of DFUs are an increasing problem in India, as are polymicrobial and gram-negative bacilli infections (28). In Detroit, MI, in the United States, MRSA has been reported as the most common multidrug-

resistant pathogen causing DFI, accounting for one-third of infections (22). In a retrospective case-control study from China, MRSA infections, both hospital-acquired and especially community-associated, were prevalent (29). Another study from China showed that MRSA accounted for 24.5% of all strains of *S. aureus* (30).

In India, DFIs commonly are caused by gram-negative bacilli (31). Furthermore, pathogens from India (32,33) and other developing nations, such as Egypt (24) and China (34), have become highly resistant to antimicrobials. DFIs in regions with warmer climates, including India, the Middle East, and Africa, most commonly are caused by *P. aeruginosa* (35), attributed in part to the warm, humid environment causing foot sweating, self-treatment with antimicrobials, and self-contamination from suboptimal perineal and hand hygiene (36,37).

A large multicenter study from Beijing, China, showed that, of the microorganisms recovered from DFIs, gram-negative bacilli accounted for 57.5%, and gram-positive bacilli accounted for 39.6%. The most prevalent microorganisms recovered were *Enterobacteriaceae* (41%) and *Staphylococcus* spp. (25.4%), of which *S. aureus* comprised 17.1%, and MRSA comprised 24.5% of all *S. aureus* isolates (30). Many patients in this study from Beijing who had DFUs, especially older adults, were receptive to receiving traditional medicines, and >50% of outpatients were prescribed antibiotics. The high incidence of self-treatment with antibiotics may have caused delays in seeking medical treat-

ment, possibly contributing to the predominance of gram-negative pathogens (30).

In Africa, some studies of DFIs have shown a predominance of gram-positive pathogens such as *S. aureus* (38,39), but one study showed that gram-negative bacilli were more common than gram-positive bacteria, with antimicrobial resistance noted in the gram-negative but not the gram-positive bacteria (40). In Morocco and Brazil, gram-negative pathogens may be more prevalent than gram-positive bacteria (41,42), and the study from Brazil showed MRSA in 22% of wounds, including one-third of MRSA strains that also were resistant to vancomycin (41).

In summary, DFI are caused primarily by gram-positive bacteria such as *S. aureus* in North America and Europe. Although *S. aureus* remains a frequent pathogen in developing countries (42), gram-negative pathogens may be predominant strains in India, Pakistan, the Middle East, Africa, China, and Brazil (28–33,39–42).

---

## Debridement: The First Step in Controlling DFIs

Establishing a healthy wound bed through adequate debridement of infected, senescent, and devitalized tissue is central to the progression of normal wound healing in diabetic ulcers. In this section, we review the minor and major excisional debridement techniques that represent current medical practice (43).

Debridement is derived from the French *débridement*, which means to remove a constraint.

The clinical definition of debridement has subsequently evolved to include the removal of nonviable or contaminated tissue that impedes normal tissue growth. Debridement enables the wound and surrounding tissue to promote normal healing by removing infection, biofilms, and senescent cells.

Ultimately, durable restoration of soft-tissue coverage is dependent on the satisfaction of a number of requisite objectives, including eradication of infection or reduction of bioburden, improvement of local blood flow, revitalization of the wound bed, and correction of biomechanical abnormalities. Debridement, when performed correctly, optimizes diabetic wound healing by meeting these objectives.

## DEBRIDEMENT TECHNIQUES

Multiple techniques are used to debride DFUs, and these can be categorized as mechanical, biological, and surgical methods. We have found the surgical approach to be the most effective. However, determining the most appropriate technique mandates the consideration of host-specific factors (e.g., comorbidities, compliance, and social support) and wound-related factors (e.g., infection/contamination status, perfusion, and viability), as well as the resources available at the treatment facility. The European Wound Management Association's guidelines for debridement provide specific information regarding the indications, contraindications, and potential adverse effects associated with each technique (44).

### **Mechanical Debridement**

Mechanical debridement includes the use of both wet-to-dry dress-

ings and dry gauze to facilitate removal of infected and nonviable tissue. Wet-to-dry dressing involves applying moist gauze to a wound, then removing it once dry and adherent to underlying tissue. Both wet-to-dry dressings and dry gauze erratically tear necrotic tissue from the underlying wound and are often painful; they are usually insufficient for adequate wound bed preparation due to fluid loss, surfacing cooling, vasoconstriction, impaired immune response, and local tissue hypoxia.

### **Biological Debridement**

**Autolytic dressings** (i.e., hydrogels, hydrocolloids, and polymeric membrane formulations) are indicated for wounds with necrotic tissue or fibrin coats and act to soften fibrotic wound margins as they stimulate release of endogenous proteolytic enzymes. Using these dressings is relatively painless, which represents a major advantage for patients, particularly those who are sensate. These dressings most often benefit patients who have minimal necrotic loads and cannot tolerate more aggressive forms of debridement.

**Enzymatic ointments**, which rely on directly hydrolyzing peptide bonds, are recommended for moist or fibrotic wounds, particularly in patients who are poor surgical candidates. Enzymes selectively digest devitalized tissue. This process causes less trauma to healthy tissue than surgical debridement, but it debrides at a very slow rate.

**Maggot debridement therapy**, using the radiated larvae of the blowfly *Phaenicia sericata*, is a proven, cost-effective alternative for treating drug-resistant, chronically infected wounds in patients who are poor surgical candidates. Maggots secrete an enzyme that

selectively dissolves necrotic tissue and biofilms into a nutrient-rich food source, while sparing healthy tissue. This process reduces the bacterial burden that often plagues gangrenous, recalcitrant wounds.

### **Surgical Debridement**

Excisional debridement can be accomplished as a minor procedure, in the clinic or at patients' bedside, or as a major procedure under regional block or general anesthesia in the operating room.

When performed as a minor procedure, excisional debridement is limited by pain (mitigable with local block or topical lidocaine) and the risk of having to deal with major bleeding. Clinic or bedside debridement can be an effective means of wound temporization or a definitive treatment in some cases and can be performed easily with local anesthetic in patients with retained sensibility.

Such minor procedures involve the use of a curette to scrape the coagulum, which contains both MMPs and biofilms, off of the wound surface. Although the underlying tissue may look clean, a curette only removes 0.5 logarithm of bacteria. Using a knife or scissors and a pickup, a surgeon can actually cut all necrotic tissue within the wound. By staying at the interface between the necrotic and viable tissue, the surgeon can minimize the risk of bleeding. Again, remember that staying at the wound surface minimally decreases the bacterial count. Any bleeding can usually be handled with direct pressure or topical silver nitrate.

As a major procedure, excisional debridement involves the direct excision of all infected, necrotic, and inflamed tissue of a wound using a combination

of knife (steel or hydrosurgical), scissors, curettes, rongeurs, power burrs, and sagittal saws. Surgical debridement is the preferred method used for situations in which urgent or emergent wound decompression is required, deeper structures (e.g., bone, joints, or tendons) are involved, and major bleeding is anticipated.

Major surgical excisional debridement procedures involve tangential excision of all grossly contaminated and devitalized tissue until only normal tissue is present. Removing the indurated and inflamed soft tissue at all borders of the wound ensures the removal of deeply buried biofilms that can easily recolonize the wound. Thin serial slicing minimizes the amount of viable tissue sacrificed, while ensuring that only healthy tissue remains. Gentle tissue handling, sharp dissection, and pinpoint or bipolar cauterization of bleeding vessels serve to minimize trauma and promote tissue viability. The surgeon should avoid harmful maneuvers such as crushing skin edges with forceps or clamps, burning tissues with electrocautery, or suture-ligating healthy perivascular tissues.

Three technical adjuncts can be used in combination to ensure adequate debridement of the entire wound: 1) topical staining of the wound surface with dye (skin marker or methylene blue), 2) use of a color-guided approach to debridement (down to healthy red, yellow, and white tissue), and 3) tangential excision of indurated or senescent wound margins. Before debridement, methylene blue with a cotton applicator or the pulled-out tip of a skin marker should be liberally applied to the wound base. This provides the

surgeon with a color reference to help in removing the entire base of the wound. In addition, the surgeon must be familiar with normal tissue colors (i.e., red [muscle and blood], white [tendon, fascia, nerve, and bone], and yellow [fat]). Using these colors as a guide provides an endpoint to debridement and helps to prevent removal of healthy tissue. Finally, excision of 3–5 mm of marginal tissue during initial debridement removes senescent cells and residual biofilms from chronic wound edges and permits healthy underlying cells to progress through the stages of normal wound healing. Pre- and post-debridement cultures should be obtained to guide future therapy. Surgical wounds may require debridement every 2–3 days until negative post-debridement cultures are obtained.

Debridement is an essential component in the management of both acute and chronic wounds because it removes infected tissue and contaminants, biofilms, and senescent cells that impede the normal progression of wound healing. The mechanical, biological, and surgical techniques described above each have a role, depending on the nature of the specific wound and patient characteristics. The appropriate use of technical adjuncts such as topical tissue staining, tangential excision, and color-guided debridement can enhance the efficiency of wound bed preparation and expedite time to closure. Although debridement methods have improved over time, there is potential for further refinement. Future prospective RCTs will aid in the establishment of evidence-based guidelines to standardize debridement practices for complex wound management.

---

## Managing Infected DFUs

Among patients with diabetes presenting with a foot wound, about half have clinical evidence of infection (10). DFIs typically begin in a break in the protective skin envelope, which allows organisms that are either introduced by trauma or colonizing the surrounding skin to gain entrance to subcutaneous tissues. Unless checked by host defenses or medical interventions, infections can spread contiguously to deeper soft tissues, including tendons, ligaments, joints, and bone. The development of a foot infection in a person with diabetes is a sentinel event; it is the most common diabetes-related reason for hospitalizations and in most countries is now the principal cause of lower-extremity amputations. The good news, however, is that recent studies have demonstrated that rapid recognition and appropriate management of DFIs can usually avert these adverse outcomes (10).

### DEFINING INFECTION

Because all open wounds will be colonized by microorganisms, we cannot define a DFI merely by the growth of microorganisms (even potentially virulent pathogens) on culture of the wound. Rather, infection is defined by the response of the host (i.e., the presence of at least two of the classic signs and symptoms of inflammation). However, these findings may be altered in patients with peripheral neuropathy or PAD, which are comorbidities in most patients with a diabetic foot wound. Thus, some clinicians accept the presence of secondary signs such as

friable granulation tissue, wound undermining, and foul odor as evidence of infection.

Once a DFI is diagnosed, classifying its severity using standardized criteria helps to define both the approach to treatment and the prognosis. Classification requires careful clinical examination of the wound and review of results of laboratory and imaging tests to determine the depth and extent of infection and whether there is bone involvement or evidence of systemic infection. Clinicians should probe such wounds to delineate their depth and seek palpable bone, which is highly suggestive of osteomyelitis, or foreign bodies. Infection involving an area of <2 cm of skin and only superficial tissues is classified as mild, whereas those with ≥2 cm of cellulitis or involving subcutaneous tissues are deemed moderate. In the forthcoming 2020 update to the IWGDF's infection classification system, the presence of bone infection (osteomyelitis) is designated separately (as "O") and is not part of the classification of moderate or severe infection (10). The presence of findings of systemic inflammatory response syndrome, especially fever or leukocytosis, defines a severe infection.

For all but the mildest DFIs, clinicians should obtain a complete blood count, as well as plain X-rays to look for foreign bodies, tissue gas, or bone abnormalities. Levels of inflammatory markers, especially serum C-reactive protein, erythrocyte sedimentation rate, and perhaps procalcitonin, may help in defining the severity and monitoring the progress of the infection (45). Advanced imaging techniques, especially magnetic

resonance imaging or radiolabeled scintigraphy, may be appropriate for some patients in whom the presence or absence of osteomyelitis is uncertain, or when planning a surgical intervention (46). Definitively diagnosing bone infection requires aseptically collecting a bone specimen either during surgery or percutaneously. Findings of a positive culture or histological evidence of inflammation and necrosis (preferably both) are the criterion standard for diagnosing osteomyelitis.

### CULTURES

A clinically uninfected diabetic foot wound should not be cultured because it does not require antimicrobial therapy. All appropriately diagnosed DFIs should be cultured to define the causative pathogens and their antibiotic susceptibilities. Tissue specimens collected by curettage or biopsy provide more specific and sensitive culture results than wound swabs. For osteomyelitis, cultures of bone more accurately reveal (and generally demonstrate fewer) pathogens than those of even deep soft tissue. Blood cultures are only needed for patients with evidence of sepsis syndrome. More recent studies using molecular microbiological (genotypic) techniques have demonstrated that, compared to standard (phenotypic) microbiology, there are considerably more microorganisms of many more species (especially obligate anaerobes) (47). What remains unclear, however, is whether it is clinically beneficial to direct antimicrobial therapy against all of these identified organisms, many of which are not classic pathogens.

### DFI TREATMENT

DFIs can progress rapidly. Thus, while awaiting the results of cultures (and any additional diagnostic studies), clinicians should initiate empiric antibiotic therapy for most DFIs. Base the choice of a regimen on the clinical characteristics and severity of the infection, any clues to the likely pathogens or recent culture results, any history of recent antibiotic therapy, and knowledge of local antibiotic resistance patterns.

The microbiology of DFIs is discussed in more detail elsewhere in this compendium (p. 6). Briefly, in Western countries, the most common pathogens are aerobic gram-positive cocci, especially *S. aureus*. For nonsevere infections, in the absence of risk factors for gram-negative pathogens (e.g., previous antibiotic therapy or hospitalization) or obligate anaerobes (e.g., ischemia or gangrene), relatively narrow-spectrum therapy (active against staphylococci and streptococci) often suffices. For severe infections, it is safer to initially prescribe a broader-spectrum regimen (48). For a clinically stable patient with a chronic infection or at risk for unusual or resistant pathogens (e.g., due to recent antibiotic treatment), discontinuing or withholding antibiotic therapy for a few days may reduce the risk of false-negative cultures.

Topical antimicrobial therapy is discussed elsewhere in this compendium (p. 15). Few data support its effectiveness for mild infections when used alone, and most DFIs require systemic antibiotic therapy (48). For severe infections, initial parenteral therapy (usually for a few days, followed by a switch to oral therapy) is often safest; otherwise, oral

antibiotic agents with good bio-availability are sufficient. Issues related to selecting predominantly oral versus IV antibiotic therapy are discussed on p. 13.

Clinicians should review patients' clinical responses to empiric therapy and their culture and sensitivity results to determine whether the selected empiric treatment regimen requires adjustment. Several factors help in determining the most appropriate definitive antibiotic regimen, including the safety, cost, and availability of various agents. It is best to follow the principles of antimicrobial stewardship: treat with the narrowest-spectrum regimen appropriate, for the shortest duration necessary (49). A key point is that antibiotics treat infections, but there is no good evidence that they help heal wounds or prevent DFIs. Thus, although a foot wound may take months to heal, antibiotic treatment of 10–14 days (until the signs and symptoms of infection resolve) is sufficient for most soft-tissue infections. The required therapy duration for bone infections is less clear, but treatment for 4–6 weeks (or shorter if all infected bone is resected) is usually adequate.

There is no evidence to support recommending any proposed adjunctive treatments (e.g., hyperbaric oxygen therapy or negative pressure wound therapy) specifically for treating DFIs. Production of biofilms by causative pathogens appears to contribute to the difficulty in eradicating infections and healing wounds, but it is not clear whether any of the currently available antibiofilm agents are clinically effective, as discussed in the sections starting on p. 4 and p. 17.

In addition to antimicrobial therapy, most patients with a DFI require some type of surgical procedure; these range from bedside sharp debridement to more extensive operative soft-tissue and bone resection. Emergent surgery is required for DFI patients with complications such as compartment syndrome, necrotizing fasciitis, or gas gangrene, but other surgical procedures are mostly considered urgent or elective. Operating surgeons must have a thorough understanding of how to drain infections that may involve several of the compartments in the foot. In general, it is best to perform surgical drainage of deep soft-tissue infection, especially abscesses, as soon as practical, rather than waiting for the infectious process to “cool off” with medical therapy.

Because most cases of DFO are chronic and accompanied by necrotic bone, surgical resection is usually the preferred treatment approach. Recent studies have demonstrated that, in about one-third of cases in which the surgeon biopsies the presumed uninfected bone at the resection margin, cultures are positive. In these cases, patients probably require further anti-infective treatment. Starting on p. 12, we discuss the issues involved in deciding when to consider non-surgical (antibiotic) treatment for DFO. Because bone infection recurs in about one-third of patients, often months after apparently successful treatment, clinicians should consider osteomyelitis as being only in remission until 1 year after treatment, after which the infection can be considered fully cured.

## **OUTCOMES OF DFI TREATMENT**

In addition to the involvement of bone in a DFI, factors that appear to decrease the likelihood of successful treatment include infection with antibiotic-resistant pathogens (especially MRSA, *P. aeruginosa*, and gram-negative bacilli with extended-spectrum  $\beta$ -lactamases) and the presence of severe PAD or end-stage renal disease. Patients with these risk factors require especially careful follow-up to ensure that the infection is responding. For patients whose infection fails to respond, consider imaging to detect previously undisclosed deep-tissue involvement that requires drainage or resection, and obtaining optimally collected specimens for repeat culture.

Despite the difficulties in diagnosing and treating DFIs, with proper management, clinicians can expect to achieve resolution of >90% of mild and moderate soft-tissue infections. Appropriate treatment can also resolve infections in >75% of DFO cases (often with minor bone resection) and severe infections (usually with surgical debridement) (10). Eliminating the clinical manifestations of infection is a key first step in managing DFIs, but patients with these infections also need appropriate wound care, including pressure off-loading, wound cleansing and debridement, revascularization of ischemic limbs, and optimized glycemic control. The best predictor of the development of a foot infection in patients with diabetes is a history of previous DFI, so clinicians should carefully follow patients who have had such infections and also teach them and their caregivers optimal prevention techniques.

---

## Surgery Versus Antibiotics in DFO

The traditional approach to patients with diabetes and foot osteomyelitis has been a surgical one. However, this approach may be associated with biomechanical changes in the foot, significant loss of quality of life, and early mortality. For these reasons, clinicians now favor a more conservative approach to DFO.

The most conservative approach is the use of antibiotics to achieve remission. Treating patients with DFO exclusively with antibiotics offers the potential to avoid hospitalization and the expense and risk involved with surgical procedures. Furthermore, it may help to avoid the biomechanical disturbances associated with surgical resection of all or part of the foot. The available evidence regarding treating DFO exclusively with antibiotics is based on several retrospective series, one prospective noncontrolled series, and one RCT (50). These series are highly heterogeneous, with variation in several factors, including the use of completely different criteria to define remission or cure of bone infection and the method of obtaining microbiological samples; exclusively empiric treatment was used in one series (51), whereas “bone debridement” as a part of the medical treatment was used in others (52).

Bone culture provides the most accurate microbiological information, and surgical or percutaneous bone biopsy is the optimal specimen collection method for obtaining a noncontaminated bone sample (50). In a series in which 52% of patients without ischemia or gangrene underwent

percutaneous bone biopsy, the remission rate was 64%, and bone culture-based antibiotic therapy was the only variable found to be associated with remission in multivariate analyses (53). Another study reported an 81% remission rate in patients in whom per-ulcer bone samples were obtained after bone debridement. The kind of bone debridement used in this series was quite similar to real surgical debridement, but it was carried out on an outpatient basis (52). Therefore, it is not possible to know the definitive role of antibiotics in this series. A remission rate of 82.3% was achieved in a series in which the authors exclusively used empiric antibiotic treatment (51). Although these series demonstrated that remission might be achieved in about two-thirds of cases, their designs precluded them from demonstrating the potential advantages of this approach (i.e., reduced cost and recurrence of ulcers) compared to surgical treatment. Furthermore, there is no information available about the timing of treatment or the clinical and radiological signs indicating that antibiotic treatment should be stopped and surgery carried out.

### CONSERVATIVE SURGERY

Surgery for DFO is required in cases involving spreading soft-tissue infection, the presence of severe infection, or where antibiotic therapy alone is likely to be ineffective. Surgical treatment could theoretically have some advantages. It removes necrotic bone, bacteria, and biofilms. Furthermore, for cases in which the ulcer is associated with bone deformities or bony prominences, surgery could correct these problems while also removing the

infection from the bone. However, although removing bone deformities seems to play a role in minimizing the risk of recurrence, this has not yet been demonstrated in a prospective study.

Over the past few years, a new surgical concept called “conservative surgery” has been established; this refers to removal of the necrotic (and much of the infected) bone and soft tissue without amputating any part of the foot. This approach has an acceptably low rate of infection recurrence (4.6%) (54). Conservative surgery aims to preserve the soft-tissue envelope and more distal tissues and is successful in treating almost half of patients admitted for DFO. Aesthetically, this approach could be an appropriate alternative to amputation for patients.

Theoretically, conservative surgery could also be a safe alternative to amputation that minimizes the risk of ulcer recurrences because it removes small pieces of bone. However, this has not yet been demonstrated. Any removal of pieces of bone leads to biomechanical disturbances. Indeed, a prospective series dealing with the outcomes of conservative surgery reported that re-ulcerations at a new site were associated with a plantar location of the ulcer during the first episode and with Charcot deformity (54). Recurrences after the removal of a metatarsal head could be as high as 41% after 13 months of follow-up (55). However, nonsurgical treatment of DFO could also be associated with a high rate of re-ulceration. Recurrences may be as high as 40% within 1 year after healing of a DFU, 60% at 3 years, and up to 65% at 5 years (56). Recurrences after nonoperative treatment frequently occur

at the same site as the previous ulceration, even despite the use of an orthosis, whereas recurrences after surgery occur at different sites due to pressure transfer.

To clarify the definitive role of surgery and exclusively antibiotic treatment when treating DFO, a group of authors designed a randomized comparative trial (7). The authors compared primarily antibiotic treatment based on deep soft-tissue microbiological samples (90 days) with primarily conservative surgical treatment (plus 10 days of antibiotics). The exclusion criteria for this study were strict: patients with severe infections, spreading soft-tissue infections, limb ischemia, necrosis, or Charcot changes. No patients with mid- or rearfoot osteomyelitis were included in the study. No differences were found between the two groups regarding healing rates (considered the remission definition), healing time, and complications requiring a subsequent surgery.

No difference in minor amputations was found between the two groups ( $P = 0.336$ ). No recurrences were found in the two groups during the follow-up period. Two re-ulcerations were detected in the antibiotic group (9.5%), and four were found in the surgical group (21%) during the 12 weeks of follow-up after healing ( $P = 0.670$ ). This study clarified some previous questions, but its small sample size and short follow-up period were important limitations. It could be concluded that, in mild and moderate cases of neuropathic nonischemic forefoot ulcers complicated by osteomyelitis, antibiotic treatment is as safe as surgery.

Based on the current medical literature and expert opinion, we

offer some conclusions. Surgery should be primarily elected in cases of:

- ▶ Severe infection, gangrene, spreading soft-tissue infection, or destruction of the soft-tissue envelope;
- ▶ Infections associated with substantial bone necrosis or progressive bone destruction despite antibiotic treatment;
- ▶ Osteomyelitis associated with deformities or biomechanical disturbances that are surgically correctable; and
- ▶ Infecting pathogens that are resistant to available antibiotics.

Antibiotics should be primarily elected in cases involving:

- ▶ Noncomplicated forefoot osteomyelitis and when bone biopsy techniques are available;
- ▶ Noncomplicated osteomyelitis for which a per-ulcer bone biopsy can be easily collected as an outpatient procedure;
- ▶ A high likelihood of poor post-operative biomechanics of the foot;
- ▶ Patients who are too medically unstable for surgery; and
- ▶ Development of osteomyelitis and critical limb ischemia while waiting for revascularization.

---

## **IV Versus Oral Antibiotics for Osteomyelitis: Lessons from the OVIVA Trial**

The conventional management of complex bone and joint infections usually comprises surgical debridement, followed by a prolonged course of IV antibiotics lasting at least 4–6 weeks (57). Alongside the inherent risk as-

sociated with IV catheters, the evidence supporting the superiority of IV administration and the belief that antibiotics given this way are somehow “stronger” for a number of infection syndromes is limited and under scrutiny (58).

The OVIVA trial (8) was a pragmatic, multicenter, parallel-group, randomized, open-label trial to assess the noninferiority of oral (PO) antibiotics compared to injectable antibiotics in bone and joint infections, including those of the diabetic foot. It was the largest clinical trial to date to assess orthopedic infection outcomes based on different antibiotic administration strategies (59). A condensed overview of the trial and its key findings has been published (8).

Researchers recruited adult patients presenting with orthopedic infections from 26 UK centers and randomly assigned them to receive either IV or PO antibiotic therapy for 6 weeks, with or without prior surgical debridement. Adult patients were eligible if they had a bone or joint infection that would normally warrant a prolonged course of antibiotics such as native bone and joint osteomyelitis, including DFO, vertebral osteomyelitis, and prosthetic joint infections. Notable exclusions were patients who did not have oral antibiotic options because of bacterial antibiotic resistance and those who had a concurrent syndrome mandating prolonged IV therapy (e.g., sepsis or endocarditis). Follow-up was for 1 year, with clinical assessments made at 6 weeks, 3 months, and 1 year.

The choice of antibiotics was made by an accredited infection specialist taking into account local epidemiology, antibiotic

**TABLE 2** Baseline Surgical Procedures Performed in Patients in the OVIVA Trial (Total N = 1,054)

|  | IV Group | PO Group | Total       |
|--|----------|----------|-------------|
| Chronic native osteomyelitis, debrided     | 153/527  | 169/527  | 322 (30.6%) |
| Chronic native osteomyelitis, not debrided | 25/527   | 29/527   | 54 (5.1%)   |
| Debridement with implant retention         | 124/527  | 123/527  | 247 (23.4%) |
| Removal of infected metalware              | 89/527   | 78/527   | 167 (15.8%) |
| Prosthetic joint implant removed           | 68/527   | 67/527   | 135 (12.8%) |
| Single-stage joint revision                | 47/527   | 43/527   | 90 (8.5%)   |
| Vertebral osteomyelitis, debrided          | 8/527    | 5/527    | 13 (1.2%)   |
| Vertebral osteomyelitis, not debrided      | 13/527   | 13/527   | 26 (2.5%)   |

Adapted from ref. 8.

resistance, drug bioavailability, allergies, drug interactions, and contraindications. Adjunctive oral rifampin as an anti-biofilm agent and antibiotic-impregnated bone cement were each permitted in both groups at the discretion of the infection specialist.

The primary outcome was the rate of definite treatment failure (based on operative findings and microbiological and histopathological criteria) as assessed by an endpoint committee blinded to the randomization strategy. Secondary outcomes included possible and probable treatment failure, serious adverse events, IV catheter complications, *Clostridium difficile* infections, early termination

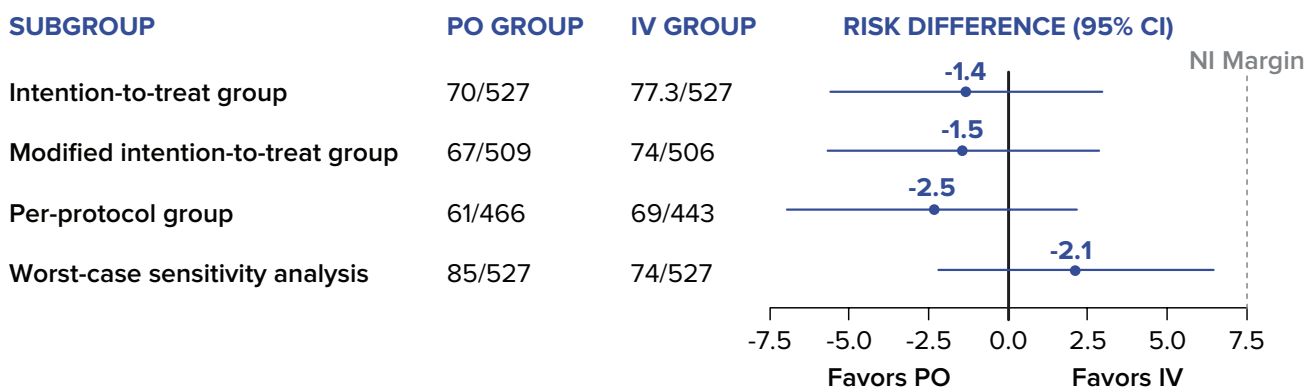
of randomized therapy, and resource utilization. The full methodological details are available in the published protocol (60).

Of 1,054 randomized patients, 39 (3.7%) were lost to follow-up with no available endpoint data. Patients in both groups were well matched in baseline characteristics such as demographics (median age 60 years, 64.3% male), surgical procedure performed (Table 2), histology (infected 51.5%, equivocal 2.8%, uninfected 6%, not performed 39.7%), and microbiology results (*Staphylococcus* spp. 64.8%, polymicrobial 18%, culture negative 15.5%). Infections of the lower limb comprised the majority of affected

sites (81.1%), with the foot accounting for 16.6%. Diabetes was the most common comorbidity (19.5%).

The primary outcome of definite treatment failure (imputed lost to follow-up) occurred in 74 of 506 patients (14.6%) in the IV group and 67 of 509 patients (13.2%) in the PO group, giving an absolute risk difference of -1.5% (95% CI -5.7 to 2.8), which satisfied the pre-specified noninferiority margin of 7.5%. Further analyses including a worst-case sensitivity analysis in which missing endpoint data were assumed to be treatment failure in the PO group and treatment success in the IV group also supported noninferiority (Figure 3).

Secondary outcomes for which the difference between the two groups was statistically significant included: 1) early discontinuation of randomized therapy (18.9% in the IV group vs. 12.8% in the PO group,  $P = 0.006$ ); 2) complications from the IV catheter (9.4% in the IV group vs. 1.0% in the PO group,  $P < 0.001$ ); and, 3) median hospital length of stay (14 days in the IV group vs. 11 days in the PO group,  $P < 0.001$ ). Secondary outcomes for which the dif-



**FIGURE 3** Risk difference in failure rates in the OVIVA trial, according to analysis performed. Failure rates are expressed as number of patients with treatment failure/total number of patients. NI, noninferiority. Adapted from ref. 8.



ference between the two groups was not statistically significant included: 1) probable or possible treatment failure (1.2% in the IV group vs. 2.0% in the PO group); 2) occurrence of at least one serious adverse event (27.7% in the IV group vs. 26.2% in the PO group); and, 3) *C. difficile* infection (1.7% in the IV group vs. 1.0% in the PO group).

Predefined and post-hoc subgroup analyses did not demonstrate an advantage toward: 1) the type of surgery performed (i.e., osteomyelitis debrided or not debrided) ( $P = 0.26$ ), retention of metalware ( $P = 0.13$ ), or antibiotic cement used ( $P = 0.98$ ); 2) infecting pathogen isolated ( $P = 0.30$ ); or, 3) presence of peripheral vascular disease ( $P = 0.47$ ), which may directly affect the delivery and concentration of antibiotic at distal sites of infection.

The most frequently used IV antibiotics were glycopeptides (41.1%) and cephalosporins (33.2%), reflecting their convenient once-daily dosing and coverage of the predominant staphylococcal infections. The quinolones (36.5%) and combination therapy (16.6%) comprising ciprofloxacin and either clindamycin or doxycycline were the most common oral antibiotics prescribed, reflecting their high oral bioavailability and bone penetration profile. Adjunctive oral rifampin for at least 6 weeks was administered in the PO group more frequently than in the IV group (22.9 vs. 31.4%) but did not significantly affect outcome. Oral follow-on therapy beyond the 6-week study period was observed in the vast majority of patients (76.7%), but the median total duration of antibiotics did not differ significantly (78 days

in the IV group vs. 71 days in the PO group).

Notable points in this study are that it is representative of real-world circumstances and pragmatic but necessarily open-label, given the logistics and risks of administering matched placebos. The vast majority of patients in this study had preceding surgery in the form of prosthesis removal or debridement, highlighting the basis of effective osteomyelitis management. The antibiotics selected were specifically tailored to be the most appropriate for each patient, but the resultant heterogeneity hindered subgroup analysis.

The OVIVA trial provided evidence that challenges the widely held belief that the treatment of osteomyelitis requires IV antibiotics. If oral regimens are appropriately selected, they can be as effective, more convenient, and less costly (with a conservative non-surgical treatment per-patient savings estimated at £2,740 GBP). More importantly, the use of oral antibiotics negates the significantly increased IV catheter-related adverse events observed in this study. Certainly, oral antibiotics are not necessarily suitable for all cases of osteomyelitis; but without a doubt, not all cases of osteomyelitis mandate the use of IV antibiotics.

---

## Topical Treatments for DFIs

As elucidated throughout this compendium, multiple comorbidities can contribute to the failure of acute wounds in the legs or feet of people with diabetes to heal, leading to the development

of chronic diabetic foot wounds. These conditions include poor arterial perfusion, impaired immune cell functions, and neuropathies. They all result in part from chronically elevated blood glucose levels that lead to non-enzymatic glycation of multiple proteins and activation of advanced glycation end products/receptor for advanced glycation end products pathways that regulate functions of inflammatory cells, neuronal cells, and wound cells (fibroblasts, epithelial cells, and vascular endothelial cells) (61). Obviously, good clinical management of these comorbidities is essential to reduce the risk of an acute wound converting into a stalled, chronic wound.

High bioburden, which is a rather poorly defined term (i.e.,  $\geq 10^5$  cfu/g of tissue), is associated with the failure of an acute wound to heal in patients with or without diabetes and is, in most wounds, a combination of both planktonic and biofilm bacteria, as well as fungal species. However, in the past 10 years, animal model studies of wound healing have demonstrated that formation of bacterial biofilms significantly delays healing (62). This evidence has led to an increased focus on the role of bacterial biofilms in impairing skin wound healing, including in patients with diabetes.

Clinical studies have now established that bacteria in the biofilm phenotype are present in a high percentage (probably >80%) of chronic skin wounds (63,64). The ability of bacteria in biofilm communities to survive under conditions that normally kill planktonic bacteria very effectively is explained by a combination of several factors

(65). These include the difficulty of phagocytic inflammatory cells (neutrophils and macrophages) to engulf and kill large masses of biofilm bacteria that are tightly attached to extracellular matrix, bone cortex, or innate surfaces such as metallic orthopedic implants. Also, the dense exopolymeric matrix of many bacterial biofilms has a high negative charge density because of acidic polysaccharides (polyalginate in *P. aeruginosa* biofilms) and free bacterial DNA that can limit diffusion of positively charged antimicrobials such as silver ions. In addition, individual bacteria located deep inside mature biofilms frequently become metabolically dormant, which provides tolerance to antibiotics that typically only kill metabolically active bacteria by interfering with essential bacterial enzyme and protein systems. This combination of factors contributes to bacterial biofilms being a major common cause of persistent infections in skin wounds and multiple other clinical conditions (66,67).

Building on this base of laboratory and clinical data about biofilms and chronic skin wounds, an international panel of wound care clinicians and basic scientists produced consensus guidelines for identification and treatment of biofilms in chronic nonhealing wounds, including DFUs (15). A key take-home message from the guidelines is that treatment of chronic DFUs should be based on the principles of biofilm-based wound care (BBWC) that emphasize a “step-down-then-step-up” approach. This approach involves starting treatment with a combination of

aggressive debridement of biofilms and topical treatments that have been shown in laboratory or clinical studies to be effective at killing residual biofilm bacteria. As the bioburden level of biofilm bacteria is reduced, the level of inflammation (neutrophils and macrophages) and the elevated levels of proteases and reactive oxygen species will also be reduced, which will allow the chronic wound to move out of a chronic inflammatory phase into an active healing (repair) phase. Topical treatments can then “step down” to less frequent and aggressive debridement combined with standard antimicrobial dressings that can effectively kill planktonic bacteria and prevent reformation of biofilm communities in the wound bed. Finally, when the DFU wound bed has been adequately prepared, topical treatments can “step up” to advanced wound treatments such as amnion/chorion dressings, growth factors, and skin grafts that will effectively stimulate healing because the proteins that comprise these advanced wound treatments and their receptors on wound cells will survive and function normally to promote healing.

#### **NEW APPROACHES TO TOPICAL TREATMENT**

Building on the principles and concepts of BBWC to control infection and inflammation, it is important to know whether new topical approaches can help control infection and inflammation and what evidence may support their use. A 2019 IWGDF systematic review (49) and a recent Cochrane systematic review (68) found no compelling published

evidence to support the use of topical antimicrobials to control (either eradicate or prevent) DFUs. However, several new topical treatments do appear to significantly reduce infection by both planktonic and biofilm bacteria based on laboratory and animal wound-healing studies, and a few pilot clinical studies have reported some improved healing. Unfortunately, there are no published, randomized, appropriately controlled, multicenter clinical studies that provide Level 1 evidence that any of these new topical treatments significantly reduce wound bacterial bioburden, including mature, tolerant biofilm bacteria, or improve healing of chronic wounds.

#### ***Localizing Bacterial Biofilms and Assessing Successful Debridement***

Two of the biggest challenges clinicians face in implementing BBWC are knowing where biofilms are located on a chronic wound bed and assessing whether the biofilms have been removed by debridement. A recent initial clinical study reported that bacterial biofilms were detected and localized on chronic wound beds using a simple and rapid membrane blotting technique followed by brief staining of the membrane with a cationic colored dye that bound to the negatively charged components of the biofilm exopolymeric matrix (69). Importantly, if no biofilm staining was detected after debridement, there was a significant reduction in generation of wound slough and a reduction in wound area in the following week compared to wounds that had residual biofilm staining on the membrane.

Another new technology (MolecuLight *i:X*) that has been reported to localize bacteria in wounds and on surrounding skin uses blue light to stimulate fluorescence of fluorochrome molecules synthesized by some strains of common wound pathogens. This technology does not appear to distinguish between planktonic and biofilm phenotypes of bacteria but may be useful in localizing bacteria in wounds to guide and assess debridement of bacteria (70).

#### ***Negative Pressure Wound Therapy Plus Instillation of Antimicrobial Solutions***

Negative pressure wound therapy (NPWT) has become a standard treatment for many types of acute and chronic wounds. This therapy primarily stimulates formation of new granulation tissue by exerting a combination of macro- and microdistortion forces on wound cells that alter patterns of gene expression and by inducing localized regions of ischemia in the wound bed. In general, NPWT alone does not dramatically reduce planktonic or biofilm bacteria in infected wounds (71). However, laboratory studies have shown dramatic reductions (>4 logarithms) in planktonic and biofilm bacteria levels on pig skin explants with mature biofilms when NPWT was combined with instillation of various antimicrobial solutions (72), and these findings were confirmed in a pilot clinical study (73). Well controlled clinical studies are needed to rigorously assess whether NPWT plus instillation reduces levels of planktonic and biofilm bacteria in DFUs and improves progression toward healing.

#### ***Concentrated Nonionic Surfactant Wound Gel***

Bacterial biofilms tend to be tightly attached (sessile) to extracellular matrix components at the surface of wound beds and in the superficial layers under the surface of the wound bed, which is one reason that simply wiping with a gauze pad does not effectively remove all biofilm bacteria (74). A recent laboratory study showed that daily application of a concentrated nonionic surfactant gel containing a preservative (Plurogel) with gauze wiping eliminated mature biofilms of *P. aeruginosa* and *S. aureus* grown on pig skin explants (75).

In summary, new topical treatments have shown positive results in significantly reducing levels of planktonic and biofilm bacteria using laboratory models of infected skin wounds. Results from clinical studies are needed to more completely understand the effects of these treatments in actual clinical use.

---

### **Role of Modern Technology in the Prevention and Management of Biofilms and DFIs**

Although biofilms are more common in chronic wounds than in acute wounds, one of the first associations of biofilms and wounds followed the electron microscopic examination of sutures and staples removed from healed surgical wounds (76). However, the fact that chronic wounds often harbor biofilms is part of the rationale linking their presence to delayed healing of such wounds

(63). Additionally, acute wounds made experimentally, inoculated with biofilm-forming bacteria, and made to induce biofilms have demonstrated delayed healing. Biofilms develop quickly, and wound-isolated *P. aeruginosa* in vitro displays characteristics of mature biofilm within 10 hours (77). As noted previously (p. 4–5), biofilms cannot be detected using routine clinical techniques. Chronic wounds lack overt clinical signs of infection, making lack of clinical suspicion a confounding problem in wound biofilm identification.

#### **TREATMENT MODALITIES**

High-quality studies are lacking and thus represent a needed opportunity with regard to elucidating the beneficial role of biofilm eradication and its relationship to healing in patients with chronic wounds. Studies to date have primarily focused on approaches that treat or prevent biofilms using in vitro or in vivo models or have involved patients using purported anti-biofilm approaches (i.e., BBWC) that result in improved healing. However, these latter studies often have not: 1) studied a single chronic wound type; 2) demonstrated the presence of biofilms before treatment; 3) demonstrated the eradication of biofilms originally present; 4) confirmed eventual healing status; or, 5) included randomized, controlled groups. Despite these significant limitations, reducing, removing, or preventing biofilms remains a logical approach to help clinicians heal chronic wounds. Table 3 lists commercially available products that have demonstrated anti-biofilm activity in vitro or with lower levels of evidence.

**TABLE 3** Commercially Available Products with Some Level of Evidence Supporting Anti-Biofilm Activity

| PRODUCT/COMPONENTS  | MECHANISM OF ACTION   |
|---|---|
| <p>Polyhexamethylene biguanide (PHMB), including:</p> <ul style="list-style-type: none"> <li>• Prontosan (B Braun)</li> <li>• PHMB and the surfactant betaine</li> <li>• Suprasorb X + PHMB (Lohmann &amp; Rauscher)</li> <li>• PuraPly AM (Organogenesis)</li> <li>• HydroClean (Hartmann) + hydro-responsive wound dressing + PHMB</li> </ul> | <p>▶ The antimicrobial activity of PHMB owes itself to its molecular shape, charge, and delivery system. It causes damage to cytoplasm membrane and prevents the efflux pump, so microbes are unable to reduce the levels of antimicrobial present.</p>   |
| Plurogel (Medline)  | <p>▶ This concentrated surfactant gel creates a moist healing environment that promotes autolytic debridement. It includes hydrophilic and hydrophobic components, the micelles of which link to form a micelle matrix. The hydrophilic surface of the micelles softens and loosens wound debris, which is then trapped by the hydrophobic inner core</p>   |
| BlastX (NextScience) (benzalkonium chloride 0.13%, polyethylene glycol, sodium citrate, citric acid, and water)   | <p>▶ BlastX dissolves the extrapolsaccharide matrix, thereby exposing 80–90% of otherwise encapsulated bacteria and allowing their removal.</p>   |
| <p>Nanoparticles (NPs)</p> <ul style="list-style-type: none"> <li>• Silver (Ag)</li> <li>• Zinc oxide (ZnO)</li> <li>• Polyethylenimine/diazoniumdiolate-doped poly(lactic-co-glycolic acid) (PLGA-PEI/NO)</li> </ul>   | <p>▶ Silver NPs capitalize on the studied antimicrobial and anti-biofilm properties of silver.</p> <p>▶ The antimicrobial and anti-biofilm activity of ZnO NPs could be caused by release of reactive oxygen species.</p> <p>▶ Nitric oxide (NO) has shown promise in dispersing biofilm; however, it needs to be supplied to the biofilm in a sustainable manner. PLGA-PEI/NO NPs aim to achieve this by supplying NO to biofilm over an extended time period.</p> |
| Lasers/photodynamic therapy   | <p>▶ Blue laser light inhibits biofilm formation in vitro and in vivo by inducing oxidative stress</p> <p>▶ A “smart” material was developed that incorporated gold nanorods and an adsorbed protease (protease-conjugated gold nanorods [PGs]). When illuminated with near-infrared light, PGs physically damage bacteria, prevent biofilm and exotoxin production, eliminate preexisting biofilm and exotoxin, and inhibit bacterial quorum-sensing systems.</p>  |
| Hypochlorous acid   | <p>▶ Use of this acid results in chemical inactivation of various cellular processes via oxidation of sulfhydryl enzymes and amino acids; chlorination of amino acids; and inhibition of protein synthesis.</p>   |
| Monofilament fiber debridement technology (MFDT; Debrisoft, Lohmann & Rauscher)   | <p>▶ Millions of polyester fibers loosen and bind debris. This product is available in pad and lolly forms.</p>   |
| Dispersin B wound spray (Kane Biotech)  | <p>▶ Enzyme isolated from <i>Aggregatibacter actinomycetemcomitans</i> breaks down poly-N-acetylglucosamine, a major polysaccharide constituent of biofilms.</p>  |
| Microlyte Ag Ga (Imbed Biosciences)   | <p>▶ This technology interferes with iron metabolism. Gallium ions compete with iron ions, resulting in inhibition of various bacterial cellular processes, including growth and biofilm production. This interaction also results in increased sensitivity to silver ions.</p>   |
| Cadexomer iodine (IODOSORB; Smith & Nephew)   | <p>▶ This spherical starch bead lattice containing 0.9% iodine as a high absorptive capacity. Iodine is slowly released as it encounters wound fluid. Iodine has a direct bactericidal effect. IODOSORB destroys biofilms, collapses glycocalyxes, and traps bacteria within beads.</p>   |

## APPROACHES TO BIOFILM TREATMENT AND PREVENTION

### *Debridement*

Physical removal of biofilm bacteria is the standard means of managing biofilms, and debridement is considered essential for effective biofilm control, most commonly with sharp debridement to remove and suppress biofilm (78). However, biofilms are often deep in wound tissue, and removal by more conservative surgical debridement techniques such as by curetting may be incomplete. Other debridement techniques such as plasma-mediated bipolar radiofrequency ablation was found to be better at least in one model (79). Even with removal, biofilms rapidly recover from mechanical disruption to reform within 24 hours, implying that debridement may best be used in combination with other treatments (80).

### *Laser and Ultrasound*

Laser treatment, particularly low-level laser therapy (LLLT), is thought to accelerate wound healing by increasing the proliferation of cells involved in wound healing and the synthesis of collagen, while also decreasing the inflammatory response. Laser therapy has also been shown to cause disaggregation of microorganisms (81). Results from LLLT studies have shown significant bactericidal potential without damaging tissue. LLLT can reduce both cell viability and biofilm growth.

In addition to lasers, ultrasound therapy has been used to investigate oral biofilms, as well as cutaneous wound healing. Noncontact ultrasonic waves can reduce biofilm in vitro and assist in bio-

film removal in vivo (82).

### *Antibiotics and Antiseptics*

Biofilms evade the host's immune system and may be up to 1,500 times more resistant to antibiotics than planktonic cells. Systemic antibiotics are not part of routine standard care for clinically noninfected DFUs, and biofilm bacteria are more resistant to topical antibiotics than planktonic bacteria. There are multiple mechanisms for biofilm antibiotic resistance: biofilms may contain a subpopulation of specialized survivor cells, the drug target may be modified or unexpressed, biofilms are less susceptible because they contain fewer growing bacteria, or the antimicrobial agent may not adequately penetrate the biofilm.

### *Anti-Biofilm Agents*

With increased knowledge of biofilm formation, anti-biofilm agents that disrupt biofilm community functions and defenses may allow other concomitant therapies and natural host mechanisms to work more effectively to promote healing. As an example, lactoferrin, a component of tears, mucus, and human milk, prevents biofilm formation by altering bacterial motility and decreasing bacterial surface attachment. Lactoferrin use in the disruption of *Pseudomonas* biofilms has been described and shown to act synergistically with xylitol, which impairs matrix development (83). Studies regarding BBWC for wound treatment in patients with critical limb ischemia have demonstrated a statistically significant increase in wound healing with BBWC (84,85). In these examples, BBWC included standard care plus lactoferrin and xylitol compounded in a methylcellulose gel as the anti-biofilm agents.

Other anti-biofilm agents include ethylenediaminetetraacetic acid, gallium, acetyl salicylic acid, and others.

Novel anti-biofilm agents currently under development include anti-adhesion molecules, quorum-sensing inhibitors, and selectively targeted antimicrobial peptides (STAMPs) (86). Given that adhesion is the first stage in biofilm formation, anti-adhesion molecules may keep bacteria in the planktonic state, making them more susceptible to the host immune system and antibiotics. Sortase, from gram-positive bacteria, is shared by most of the surface proteins and is an anti-adhesion candidate because it covalently anchors surface proteins to peptidoglycan. Quorum sensing is crucial to the maturation of biofilms; thus, using quorum-sensing inhibitors theoretically can maintain bacteria in a planktonic state by affecting cell-to-cell communication, making bacteria more susceptible to the immune system and antibiotics. Two leading candidates for quorum-sensing inhibitors include the furanones and ribonucleic acid III inhibiting peptide. Species-specific control of biofilms may be achieved with STAMPs, which are an essential part of the innate immune system that contain species-specific binding domains.

### *Biofilm Extracellular Enzymes*

Other novel strategies include matrix-degrading enzymes, which degrade the protective polysaccharide layer and make cells more susceptible to antibiotics (78). The final stage of the biofilm life cycle, dispersion, allows bacteria to release from the biofilm and colonize other areas. However, dispersion results in an increased

number of easier-to-eradicate planktonic bacteria and thus is a therapeutic topic of interest. To facilitate dispersion, bacteria produce extracellular enzymes such as glycosidases, proteases, and deoxyribonucleases that degrade the adhesive components in the biofilm matrix. Two common wound pathogens, *P. aeruginosa* and *S. aureus*, produce enzymes that can degrade the biofilm matrix. As an example, *P. aeruginosa*-produced alginate lyase increases biofilm cell detachment and antibiotic effectiveness (86). The enzyme dispersin B is able to degrade the polysaccharide matrix of staphylococci and is being developed as a wound care gel. Other matrix-degrading enzymes include deoxyribonuclease, lysostaphin, proteinase K, and trypsin.

### **Vaccination**

New treatment strategies are being explored, including the potential of vaccination against pathogens. In the area of oral biofilms, numerous studies have documented effective vaccination against oral pathogens (78). Often, biofilms are polymicrobial, and some bacteria, such as *Fusobacterium nucleatum* in the mouth, bridge other species within the biofilm community.

Finally, there is great interest in developing passive immunotherapy or vaccines for bacterial infections such as staphylococci. Vaccine targeting can disrupt biofilm attachment and growth. Bacteriophages (viruses that affect bacteria) can be used effectively in managing infection, mainly because of their bactericidal activity. Studies involving the interaction of bacteriophages and biofilms have shown that phages can degrade biofilm exopolysac-

charide and infect biofilm cells, when experimentally tracing the interaction of bacteriophage with bacterial biofilms using fluorescent and chromogenic probes.

---

## **Conclusion**

The worldwide burden of diabetic foot complications—particularly DFUs—has been growing (1,56). In this compendium, we have reviewed a number of promising strategies to heal wounds, in addition to some essentials of care such as high-quality surgical wound debridement and off-loading of pressure (56). We have also included treatments that have received increased support in the literature such as cultured tissue products, topical oxygen therapy, sucrose octasulfate dressings, and autologous platelet-rich fibrin dressings (2–6).

Importantly, major strides have occurred in the management of wound infection during the past decade, and these are also summarized herein. Whereas clinically noninfected wounds do not require antibiotic therapy, we have explained that infected wounds should be cultured, taking tissue from the wound base after debridement, and that antibiotic therapy should be targeted appropriately. Undoubtedly, the results of the OVIVA trial will engender much debate in the near future about the need for IV antibiotics in osteomyelitis.

Although we have made advances in approaches to tissue repair and wound healing, our knowledge of the constantly changing wound milieu remains elusive. Indeed, the development of companion diagnostics and biomarkers to help direct therapy

is an important goal. Last year, the U.S. National Institute of Diabetes and Digestive and Kidney Diseases highlighted this need by creating a consortium dedicated to advancing this nascent field (87). We believe it is highly likely that numerous future therapeutics will come bundled with a companion diagnostic to help target when or whether it is likely to be most effective.

Measuring what we manage is of course crucially important. However, globally accepted definitions of risk are arguably even more central to high-quality care. In the past year, the IWGDF and the Global Vascular Guidelines Writing Group both published important efforts to define risk and better guide care worldwide (10,88). Both groups have made efforts to refine the terminology for PAD. Instead of the previous term “critical limb ischemia,” or CLI, the preferred term is now “chronic limb-threatening ischemia,” or CLTI (88). This new term better describes the condition and marries well with the concept of chronic DFUs. In addition, a more universally accepted and validated definition of limb threats (“wound, ischemia, and foot infection,” or WIfI) is becoming the new norm in interdisciplinary teams (88,89). WIfI classification allows clinicians to measure and communicate the multifactorial and dynamic nature of diabetic foot disease with an easily understood scoring system. This is similar in nature to the use of “tumor, node, metastasis,” or TNM, terminology in the field of oncology.

Although healing wounds remains a key goal, one could argue that it is a bit too narrow a focus. Indeed, after a wound heals,

40% of people with diabetes will re-ulcerate within 1 year, and nearly two-thirds will do so by 3 years (56). Thus, recurrence is not only common, it is likely. The foot in diabetes, once healed, is in remission.

Our goals, as mentioned in the first compendium (1), must focus on innovation in methods to maximize ulcer-free, hospitalization-free, and activity-rich days. As we have shown, much progress has been made toward this end, but there is much work yet to do. We hope this volume will help readers with the early detection, identification, and treatment of infection in diabetic feet, for it is infection in neuroischemic ulcers that often leads to amputation.

#### ACKNOWLEDGMENTS

The authors thank Dr. Elly Trepman for review and helpful suggestions on the section concerning the microbiology of DFIs.

Editorial and project management services were provided by Debbie Kendall of Kendall Editorial in Richmond, VA.

#### AUTHOR CONTRIBUTIONS

A.J.M.B. and D.G.A. served as co-editors and, as such, co-wrote the introduction and conclusion and reviewed and edited the entire manuscript. M.J.H. wrote “How Infection Impairs Wound Healing.” M.M. wrote “Biofilms in the Context of DFUs.” J.M.E. wrote “Evolving Microbiology of DFIs.” C.E.A. wrote “Debridement: The First Step in Controlling DFIs.” B.A.L. wrote “Managing Infected DFUs.” J. A.-S. wrote “Surgery Versus Antibiotics in DFO.” H.K.L. wrote “IV Versus Oral Antibiotics for Osteomyelitis: Lessons from the OVIVA Trial.” G.S. wrote “Topical Treatments for DFIs.” R.S.K. wrote “Role of Modern Technology in

the Prevention and Management of Biofilms and DFIs.” A.J.M.B. and D.G.A. are the guarantors of this work.

#### DUALITIES OF INTEREST

A.J.M.B., D.G.A., M.J.H., J.M.E., C.E.A., B.A.L., J.A.-S., G.S., and R.S.K. have no relevant dualities of interest to disclose. M.M. has received research grants and consultant fees for educational activities from Smith & Nephew in the area of wound biofilm. The work of H.K.L. was funded by the National Institute for Health Research—Health Training Assessment.

#### REFERENCES

1. Boulton AJM, Armstrong DG, Kirsner RS, et al. *Diagnosis and Management of Diabetic Foot Complications*. American Diabetes Association, Arlington, VA, 2018
2. Edmonds M. A renaissance in diabetic foot care: new evidence-based treatments. *Lancet Diabetes Endocrinol* 2018;6:837–838
3. Game F, Jeffcoate W, Tarnow L, et al.; LeucoPatch II Trial Team. LeucoPatch system for the management of hard-to-heal diabetic foot ulcers in the UK, Denmark, and Sweden: an observer-masked, randomised controlled trial. *Lancet Diabetes Endocrinol* 2018;6:870–878
4. Niederauer MQ, Michalek JE, Liu Q, Papas KK, Lavery LA, Armstrong DG. Continuous diffusion of oxygen improves diabetic foot ulcer healing when compared with a placebo control: a randomised, double-blind, multicentre study. *J Wound Care* 2018;27(Suppl. 9):S30–S45
5. Frykberg RG, Franks PJ, Edmonds M, et al., on behalf of the TWO2 Study Group. A multinational, multicenter, randomized, double-blinded, placebo-controlled trial to evaluate the efficacy of cyclical topical wound oxygen therapy (TWO2) in the treatment of chronic diabetic foot ulcers: the TWO2 study. *Diabetes Care*. Epub ahead of print on 16 October 2019 (doi: 10.2337/dc19-0476)
6. Edmonds M, Lázaro-Martínez JL, Alfayate-García JM, et al. Sucrose octasulfate dressing versus control dressing in patients with neuroischaemic diabetic foot ulcers (Explorer): an international, multicentre, double-blind, randomised, controlled trial. *Lancet Diabetes Endocrinol* 2018;6:186–196
7. Lázaro-Martínez JL, Aragón-Sánchez J, García-Morales E. Antibiotics versus conservative surgery for treating diabetic foot osteomyelitis: a randomized comparative trial. *Diabetes Care* 2014;37:789–795
8. Li HK, Rombach I, Zambellas R, et al.; OVIVA Trial Collaborators. Oral versus intravenous antibiotics for bone and joint infection. *N Engl J Med* 2019;380:425–436
9. Brem H, Stojadinovic O, Diegelmann RF, et al. Molecular markers in patients with chronic wounds to guide surgical debridement. *Mol Med* 2007;13:30–39
10. Lipsky BA, Senneville E, Abbas ZG, et al. IWGDF guideline on the diagnosis and treatment of foot infection in persons with diabetes. *Diabet Metab Res Rev*. In press. Also available from [iwgdfguidelines.org/wp-content/uploads/2019/05/05-IWGDF-infection-guideline-2019.pdf](http://iwgdfguidelines.org/wp-content/uploads/2019/05/05-IWGDF-infection-guideline-2019.pdf). Accessed 5 November 2019
11. Lipsky BA, Berendt AR, Cornia PB, et al.; Infectious Diseases Society of America. 2012 Infectious Diseases Society of America clinical practice guideline for the diagnosis and treatment of diabetic foot infections. *Clin Infect Dis* 2012;54:e132–e173
12. Prompers L, Huijberts M, Apelqvist J, et al. High prevalence of ischaemia, infection and serious comorbidity in

- patients with diabetic foot disease in Europe: baseline results from the Eurodiale study. *Diabetologia* 2007;50:18–25
13. Kalan LR, Brennan MB. The role of the microbiome in nonhealing diabetic wounds. *Ann N Y Acad Sci* 2019;1435:79–92
14. Williams H, Campbell L, Crompton RA, et al. Microbial host interactions and impaired wound healing in mice and humans: defining a role for BD14 and NOD2. *J Invest Dermatol* 2018;138:2264–2274
15. Schultz G, Bjarnsholt T, James GA, et al.; Global Wound Biofilm Expert Panel. Consensus guidelines for the identification and treatment of biofilms in chronic nonhealing wounds. *Wound Repair Regen* 2017;25:744–757
16. Ruffin M, Brochiero E. Repair process impairment by *Pseudomonas aeruginosa* in epithelial tissues: major features and potential therapeutic avenues. *Front Cell Infect Microbiol* 2019;9:182
17. Kalan LR, Meisel JS, Loesche MA, et al.; Strain- and species-level variation in the microbiome of diabetic wounds is associated with clinical outcomes and therapeutic efficacy. *Cell Host Microbe* 2019;25:641–655.e5
18. Høiby N, Bjarnsholt T, Moser C, et al.; ESCMID Study Group for Biofilms and Consulting External Expert Werner Zimmerli. ESCMID guideline for the diagnosis and treatment of biofilm infections 2014. *Clin Microbiol Infect* 2015;21(Suppl. 1):S1–S25
19. Johani K, Malone M, Jensen S, et al. Microscopy visualisation confirms multi-species biofilms are ubiquitous in diabetic foot ulcers. *Int Wound J* 2017;14:1160–1169
20. Johani K, Fritz BG, Bjarnsholt T, et al. Understanding the microbiome of diabetic foot osteomyelitis: insights from molecular and microscopic approaches. *Clin Microbiol Infect* 2019;25:332–339
21. Lipsky BA, Berendt AR, Deery HG, et al.; Infectious Diseases Society of America. Diagnosis and treatment of diabetic foot infections. *Clin Infect Dis* 2004;39:885–910
22. Henig O, Pogue JM, Cha R, et al. Epidemiology of diabetic foot infection in the metro-Detroit area with a focus on independent predictors for pathogens resistant to recommended empiric antimicrobial therapy. *Open Forum Infect Dis* 2018;5:ofy245
23. Tascini C, Lipsky BA, Iacopi E, et al. KPC-producing *Klebsiella pneumoniae* rectal colonization is a risk factor for mortality in patients with diabetic foot infections. *Clin Microbiol Infect* 2015;21:790.e1–e3
24. Hassan MA, Tamer TM, Rageh AA, Abou-Zeid AM, Abd El-Zaher EHF, Kenawy ER. Insight into multidrug-resistant microorganisms from microbial infected diabetic foot ulcers. *Diabetes Metab Syndr* 2019;13:1261–1270
25. Tentolouris N, Jude EB, Smirnof I, Knowles EA, Boulton AJ. Methicillin-resistant *Staphylococcus aureus*: an increasing problem in a diabetic foot clinic. *Diabet Med* 1999;16:767–771
26. Dang CN, Prasad YD, Boulton AJ, Jude EB. Methicillin-resistant *Staphylococcus aureus* in the diabetic foot clinic: a worsening problem. *Diabet Med* 2003;20:159–161
27. King MD, Humphrey BJ, Wang YF, Kourbatova EV, Ray SM, Blumberg HM. Emergence of community-acquired methicillin-resistant *Staphylococcus aureus* USA 300 clone as the predominant cause of skin and soft-tissue infections. *Ann Intern Med* 2006;144:309–317
28. Viswanathan V, Pendsey S, Radhakrishnan C, Rege TD, Ahdal J, Jain R. Methicillin-resistant *Staphylococcus aureus* in diabetic foot infection in India: a growing menace. *Int J Low Extrem Wounds* 2019;18:236–246
29. Wang SH, Sun ZL, Guo YJ, et al. Methicillin-resistant *Staphylococcus aureus* isolated from foot ulcers in diabetic patients in a Chinese care hospital: risk factors for infection and prevalence. *J Med Microbiol* 2010;59:1219–1224
30. Li X, Qi X, Yuan G, et al. Microbiological profile and clinical characteristics of diabetic foot infection in northern China: a retrospective multicentre survey in the Beijing area. *J Med Microbiol* 2018;67:160–168
31. Ramakant P, Verma AK, Misra R, et al. Changing microbiological profile of pathogenic bacteria in diabetic foot infections: time for a rethink on which empirical therapy to choose? *Diabetologia* 2011;54:58–64
32. Zubair M, Ahmad J. Potential risk factors and outcomes of infection with multidrug resistance among diabetic patients having ulcers: 7 years study. *Diabetes Metab Syndr* 2019;13:414–418
33. Miyan Z, Fawwad A, Sabir R, Basit A. Microbiological pattern of diabetic foot infections at a tertiary care center in a developing country. *J Pak Med Assoc* 2017;67:665–669
34. Wu M, Pan H, Leng W, Lei X, Chen L, Liang Z. Distribution of microbes and drug susceptibility in patients with diabetic foot infections in Southwest China. *J Diabetes Res* 2018;2018:9817308
35. Spichler A, Hurwitz BL, Armstrong DG, Lipsky BA. Microbiology of diabetic foot infections: from Louis Pasteur to ‘crime scene investigation.’ *BMC Med* 2015;13:2
36. Leung HB, Ho YC, Wong WC, Guerin J. Seasonal variations in



- non-traumatic major lower limb amputation in Hong Kong Chinese diabetic patients. *Hong Kong Med J* 2007;13:379–381
37. Uçkay I, Aragón-Sánchez J, Lew D, Lipsky BA. Diabetic foot infections: what have we learned in the last 30 years? *Int J Infect Dis* 2015;40:81–91
38. Uçkay I, Gariani K, Pataky Z, Lipsky BA. Diabetic foot infections: state-of-the-art. *Diabetes Obes Metab* 2014;16:305–316
39. Mutonga DM, Mureithi MW, Ngugi NN, Otieno FCF. Bacterial isolation and antibiotic susceptibility from diabetic foot ulcers in Kenya using microbiological tests and comparison with RT-PCR in detection of *S. aureus* and MRSA. *BMC Res Notes* 2019;12:244
40. Belefquih B, Frikh M, Benlahlou Y, et al. Diabetic foot infection in Morocco: microbiological profile. *Wounds* 2016;28:89–98
41. Perim MC, Borges Jda C, Celeste SR, et al. Aerobic bacterial profile and antibiotic resistance in patients with diabetic foot infections. *Rev Soc Bras Med Trop* 2015;48:546–554
42. Jaju K, Pichare A, Davane M, Nagoba B. Profile and antibiotic susceptibility of bacterial pathogens associated with diabetic foot ulcers from a rural area. *Wounds* 2019;31:158–162
43. Anghel EL, DeFazio MV, Barker JC, Janis JE, Attinger CE. Current concepts in debridement: science and strategies. *Plast Reconstr Surg* 2016;138(Suppl. 3):82S–93S
44. Strohal R, Dissemond J, Jordan O'Brien J, et al. EWMA document: debridement: an updated overview and clarification of the principle role of debridement. *J Wound Care* 2013;22:5
45. Senneville E, Abbas ZG, Aragón-Sánchez J, et al. Diagnosis of infection in the foot in diabetes: a systematic review. *Diabetes Metab Res Rev* 2019. In press
46. Lauri C, Tamminga M, Glaudemans AWJM, et al. Detection of osteomyelitis in the diabetic foot by imaging techniques: a systematic review and meta-analysis comparing MRI, white blood cell scintigraphy, and FDG-PET. *Diabetes Care* 2017;40:1111–1120
47. Pereira SG, Moura J, Carvalho E, Empadinhas N. Microbiota of chronic diabetic wounds: ecology, impact, and potential for innovative treatment strategies. *Front Microbiol* 2017;8:1791
48. Peters EJG, Senneville E, Abbas ZG, et al. Interventions in the management of infection in the foot in diabetes: a systematic review (update). *Diabetes Metab Res Rev*. In press
49. Uçkay I, Berli M, Sendi P, Lipsky BA. Principles and practice of antibiotic stewardship in the management of diabetic foot infections. *Curr Opin Infect Dis* 2019;32:95–101
50. Aragón-Sánchez J, Lipsky BA. Modern management of diabetic foot osteomyelitis: the when, how and why of conservative approaches. *Expert Rev Anti Infect Ther* 2018;16:35–50
51. Game FL, Jeffcoate WJ. Primarily non-surgical management of osteomyelitis of the foot in diabetes. *Diabetologia* 2008;51:962–967
52. Lesens O, Desbiez F, Vidal M, et al. Culture of per-wound bone specimens: a simplified approach for the medical management of diabetic foot osteomyelitis. *Clin Microbiol Infect* 2011;17:285–291
53. Senneville E, Lombart A, Beltrand E, et al. Outcome of diabetic foot osteomyelitis treated nonsurgically: a retrospective cohort study. *Diabetes Care* 2008;31:637–642
54. Aragón-Sánchez J, Lázaro-Martínez JL, Hernández-Herrero C, et al. Does osteomyelitis in the feet of patients with diabetes really recur after surgical treatment? Natural history of a surgical series. *Diabet Med* 2012;29:813–818
55. Molines-Barroso RJ, Lázaro-Martínez JL, Aragón-Sánchez J, García-Morales E, Beneit-Montesinos JV, Álvaro-Afonso FJ. Analysis of transfer lesions in patients who underwent surgery for diabetic foot ulcers located on the plantar aspect of the metatarsal heads. *Diabet Med* 2013;30:973–976
56. Armstrong DG, Boulton AJM, Bus SA. Diabetic foot ulcers and their recurrence. *N Engl J Med* 2017;376:2367–2375
57. Lew DP, Waldvogel FA. Osteomyelitis. *Lancet* 2004;364:369–379
58. Li HK, Agweyu A, English M, Bejon P. An unsupported preference for intravenous antibiotics. *PLoS Med* 2015;12:e1001825
59. Conterno LO, Turchi MD. Antibiotics for treating chronic osteomyelitis in adults. *Cochrane Database Syst Rev* 2013;9:CD004439
60. Li HK, Scarborough M, Zambellas R, et al. Oral versus intravenous antibiotic treatment for bone and joint infections (OVIVA): study protocol for a randomised controlled trial. *Trials* 2015;16:583
61. Schultz G, Acosta JB, Cowan L, Stechmiller J. Linking the advanced glycation endproducts/receptor for advanced glycation endproducts pathway in diabetics with with inflammation and topical antiinflammatory treatments of chronic wounds. *Adv Wound Care (New Rochelle)* 2010;1:248–253
62. Schierle CF, De la Garza M, Mustoe TA, Galiano RD. Staphylococcal biofilms impair wound healing by delaying reepithelialization in a murine

- cutaneous wound model. *Wound Repair Regen* 2009;17:354–359
63. James GA, Swogger E, Wolcott R, et al. Biofilms in chronic wounds. *Wound Repair Regen* 2008;16:37–44
64. Malone M, Bjarnsholt T, McBain AJ, et al. The prevalence of biofilms in chronic wounds: a systematic review and meta-analysis of published data. *J Wound Care* 2017;26:20–25
65. Fux CA, Costerton JW, Stewart PS, Stoodley P. Survival strategies of infectious biofilms. *Trends Microbiol* 2005;13:34–40
66. Costerton JW, Stewart PS, Greenberg EP. Bacterial biofilms: a common cause of persistent infections. *Science* 1999;284:1318–1322
67. del Pozo JL, Patel R. The challenge of treating biofilm-associated bacterial infections. *Clin Pharmacol Ther* 2007;82:204–209
68. Dumville JC, Lipsky BA, Hoey C, Cruciani M, Fison M, Xia J. Topical antimicrobial agents for treating foot ulcers in people with diabetes. *Cochrane Database Syst Rev* 2017;6:CD011038
69. Nakagami G, Schultz G, Gibson DJ, et al. Biofilm detection by wound blotting can predict slough development in pressure ulcers: a prospective observational study. *Wound Repair Regen* 2017;25:131–138
70. Rennie MY, Lindvere-Teene L, Tapang K, Linden R. Point-of-care fluorescence imaging predicts the presence of pathogenic bacteria in wounds: a clinical study. *J Wound Care* 2017;26:452–460
71. Weed T, Ratliff C, Drake DB. Quantifying bacterial bioburden during negative pressure wound therapy: does the wound VAC enhance bacterial clearance? *Ann Plast Surg* 2004;52:276–279
72. Phillips PL, Yang Q, Schultz GS. The effect of negative pressure wound therapy with periodic instillation using antimicrobial solutions on *Pseudomonas aeruginosa* biofilm on porcine skin explants. *Int Wound J* 2013;10(Suppl. 1):48–55
73. Yang C, Goss SG, Alcantara S, Schultz G, Lantis IJ. Effect of negative pressure wound therapy with instillation on bioburden in chronically infected wounds. *Wounds* 2017;29:240–246
74. Fazli M, Bjarnsholt T, Kirketerp-Møller K, et al. Nonrandom distribution of *Pseudomonas aeruginosa* and *Staphylococcus aureus* in chronic wounds. *J Clin Microbiol* 2009;47:4084–4089
75. Yang Q, Larose C, Della Porta AC, Schultz GS, Gibson DJ. A surfactant-based wound dressing can reduce bacterial biofilms in a porcine skin explant model. *Int Wound J* 2017;14:408–413
76. Gristina AG, Price JL, Hobgood CD, Webb LX, Costerton JW. Bacterial colonization of percutaneous sutures. *Surgery* 1985;98:12–19
77. Harrison-Balestra C, Cazzaniga AL, Davis SC, Mertz PM. A wound-isolated *Pseudomonas aeruginosa* grows a biofilm in vitro within 10 hours and is visualized by light microscopy. *Dermatol Surg* 2003;29:631–635
78. Mancini KA, Kirsner RS, Ajdic D. Wound biofilms: lessons learned from oral biofilms. *Wound Repair Regen* 2013;21:352–362
79. Nusbaum AG, Gil J, Rippey MK, et al. Effective method to remove wound bacteria: comparison of various debridement modalities in an in vivo porcine model. *J Surg Res* 2012;176:701–707
80. Cooper R, Okhiria O. Biofilms, wound infection and the issue of control. *Wounds UK* 2006;2:48–57
81. Basso FG, Oliveira CF, Fontana A, et al. In vitro effect of low-level laser therapy on typical oral microbial biofilms. *Braz Dent J* 2011;22:502–510
82. Nishikawa T, Yoshida A, Khanal A, et al. A study of the efficacy of ultrasonic waves in removing biofilms. *Gerodontology* 2010;27:199–206
83. Snyder RJ, Bohn G, Hanft J, et al. Wound biofilm: current perspectives and strategies on biofilm disruption and treatments. *Wounds* 2017;29:S1–S17
84. Black CE, Costerton JW. Current concepts regarding the effect of wound microbial ecology and biofilms on wound healing. *Surg Clin North Am* 2010;90:1147–1160
85. Wolcott RD, Rhoads DD. A study of biofilm-based wound management in subjects with critical limb ischaemia. *J Wound Care* 2008;17:145–148, 150–152, 154–155
86. Alkawash MA, Soothill JS, Schiller NL. Alginate lyase enhances antibiotic killing of mucoid *Pseudomonas aeruginosa* in biofilms. *APMIS* 2006;114:131–138
87. National Institute of Diabetes and Digestive and Kidney Diseases. Diabetic foot consortium—biomarker meeting. Available from [www.niddk.nih.gov/news/meetings-workshops/2018/diabetic-foot-consortium-biomarkers](http://www.niddk.nih.gov/news/meetings-workshops/2018/diabetic-foot-consortium-biomarkers). Accessed 28 October 2019
88. Conte MS, Bradbury AW, Kolh P, et al. Global vascular guidelines on the management of chronic limb-threatening ischemia. *J Vasc Surg* 2019;69(Suppl. 6):3S–125S.e40
89. Mills JL Sr, Conte MS, Armstrong DG, et al.; Society for Vascular Surgery Lower Extremity Guidelines Committee. The Society for Vascular Surgery Lower Extremity Threatened Limb Classification System: risk stratification based on wound, ischemia, and foot infection (WIFI). *J Vasc Surg* 2014;59:220–234.e1–2

Suggested citation:

Boulton AJM, Armstrong DG, Hardman MJ, et al. *Diagnosis and Management of Diabetic Foot Infections*. Arlington, Va., American Diabetes Association, 2020 (<https://doi.org/10.2337/db2020-01>)



