

History

A female in her fifties with a 1 year history of a non-healing medial right calf wound. According to patient, the wound was precipitated by an insect bite which resulted in a failed surgical closure. Patient has a significant history of HTN, osteoarthritis, fem-pop. bypass and right femoral angioplasty. Patient ambulates with a walker and brace support and has significant financial limitations due to inability to work.

Initial Presentation

- Ulcer measured 3.5cm X 1.5cm X 0.2cm depth
- Purulent malodorous exudate
- + palpable pulses
- Peri-wound erythema and induration
- Significant continuous pain
- Full thickness tissue involvement with irregularly shaped margins

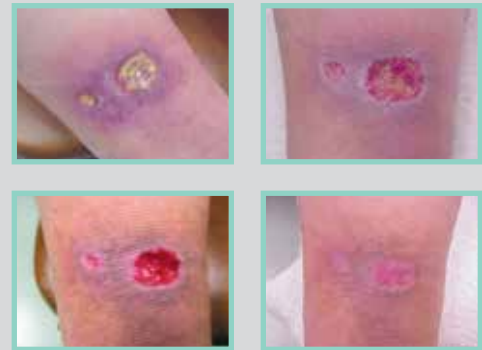
Wound Healing Management

Week 1 Consults to MSW for financial assistance, Orthotist to address ambulation issues, Pain Clinic, and Neurology.

* Insurance company authorized only 3 visits which created a delay in follow through and wound deterioration... Once consistency achieved – wound healing occurred.

Week 11 Autolytic debridement.

Week 13 Unna boot application.



Results

Week 23 Wound epithelialized and free of pain.

Referral Information

Patients are referred to the Wound Care Center® for aggressive, outcome based wound management. Our services are designed to complement the attending physician's services by providing expert wound management consultation and care including the application of advanced wound care technology based on a comprehensive system of evidence based clinical practice guidelines. The referring physician will continue to treat co-morbid conditions and provide for the patient's overall medical care. All etiologies of wound healing failure are accepted for evaluation and care.

Types of wounds treated include Diabetic, Venous Stasis, Ischemic, Pressure, Traumatic, Surgical and other wounds that resist healing.

Problem wound patients should be referred to the Center when:

- The wound has failed to show significant progress in 4 weeks of standard care
- The wound involves deep tissue structures or is limb or life threatening
- The wound is complicated by significant comorbidities including peripheral vascular disease, persistent edema, persistent infection, prior radiation treatment to the area, or compromised immune status of the patient